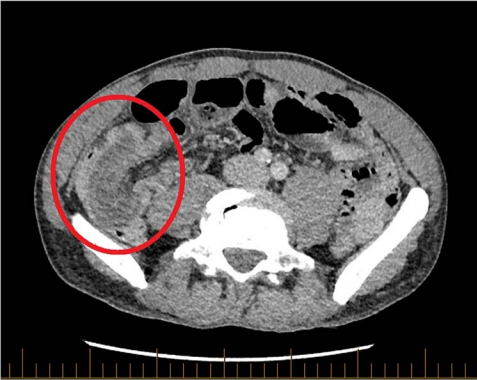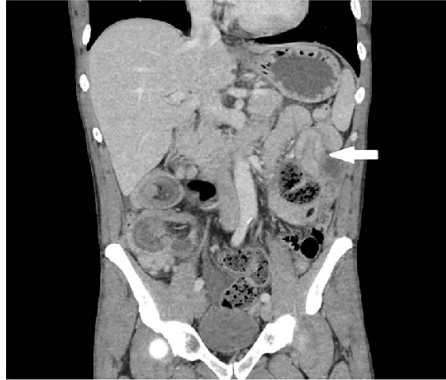
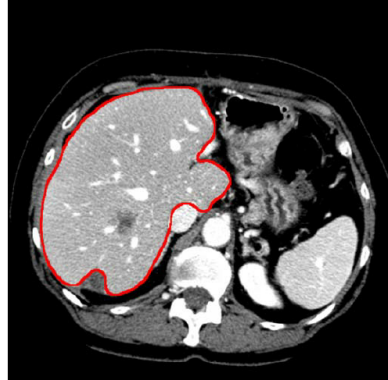


Axial CT of the abdomen and pelvis with portal venous contrast. Long segment of ileocolic intussusception shown (red circle).



Coronal CT for abdomen and pelvis with portal venous. Jejunal intussusception in left upper quadrant (white arrow).



Contour of the liver segmentation (in red) compared to the original CT scan slice