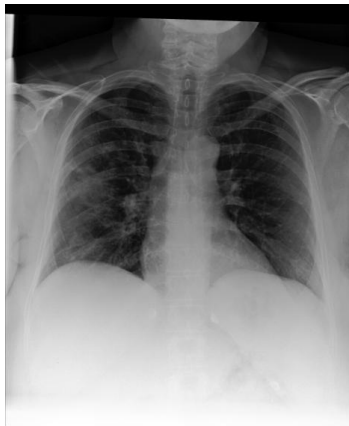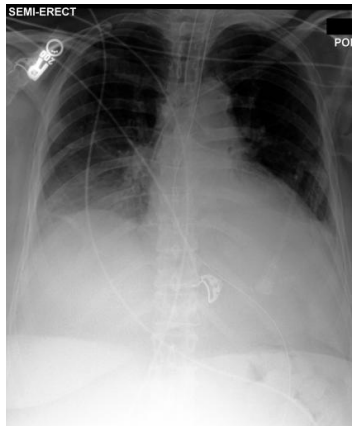


Main Image



Reference Image

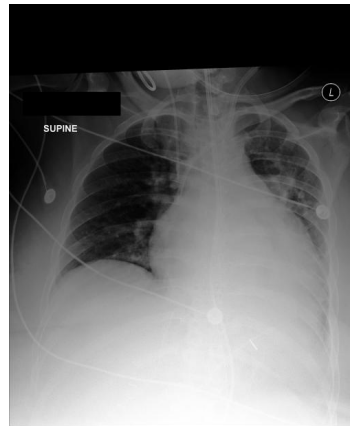

Question: What has changed compared to the reference image ?

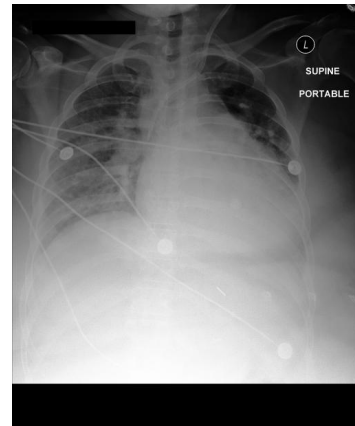
Ground Truth: The main image has additional findings of pneumonia, and lung opacity than the reference image. The main image is missing the findings of pleural effusion, and atelectasis than the reference image.

Our model: The main image has additional findings of pneumonia, and lung opacity than the reference image. The main image is missing the findings of pleural effusion, and atelectasis than the reference image.

Main Image



Reference Image



Question: What has changed compared to the reference image ?

Ground Truth: The main image has an additional finding of enlargement of the cardiac silhouette than the reference image. The main image is missing the findings of cardiomegaly, and lung opacity than the reference image.

Our model: The main image has an additional finding of cardiomegaly than the reference image. The main image is missing the findings of enlargement of the cardiac silhouette, and lung opacity than the reference.