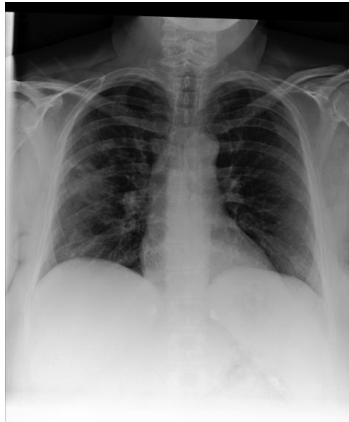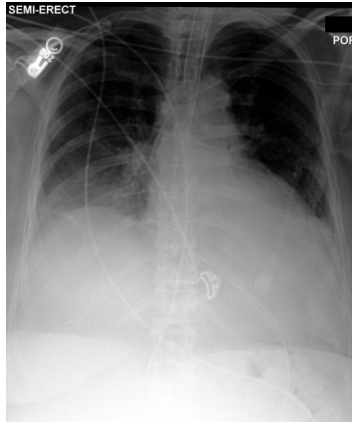


Main Image



Reference Image

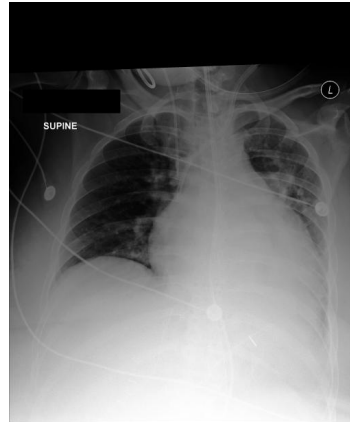

Question: What has changed compared to the reference image ?

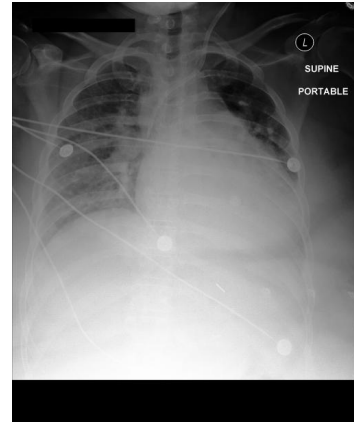
Ground Truth: The main image **has** additional findings of **pneumonia**, and **lung opacity** than the reference image. The main image is **missing** the findings of **pleural effusion**, and **atelectasis** than the reference image.

Our model: The main image **has** additional **findings** of **pneumonia**, and **lung opacity** than the reference image. The main image is **missing** the findings of **pleural effusion**, and **atelectasis** than the reference image.

Main Image



Reference Image



Question: What has changed compared to the reference image ?

Ground Truth: The main image **has** an additional finding of **enlargement of the cardiac silhouette** than the reference image. The main image is **missing** the findings of **cardiomegaly**, and **lung opacity** than the reference image.

Our model: The main image **has** an additional finding of **cardiomegaly** than the reference image. The main image is **missing** the findings of **enlargement of the cardiac silhouette**, and **lung opacity** than the reference image.