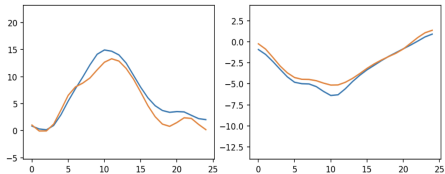


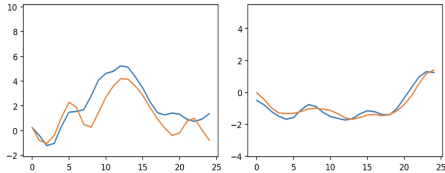
dilated cardiomyopathy

radial

circumferential



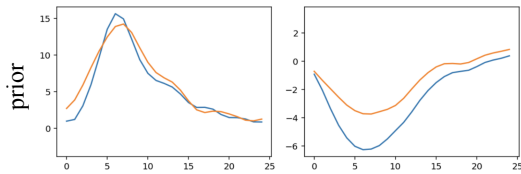
no prior



hypertrophic cardiomyopathy

radial

circumferential



no prior

