

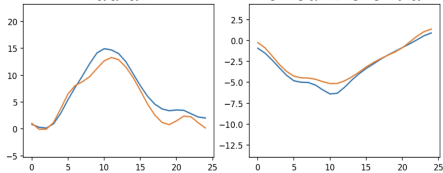
dilated cardiomyopathy

hypertrophic cardiomyopathy

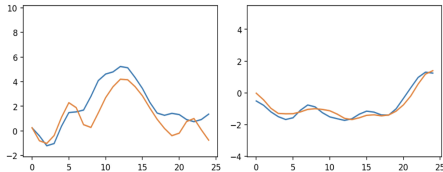
prior

radial

circumferential

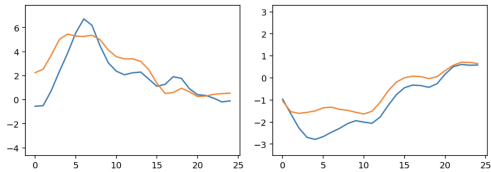
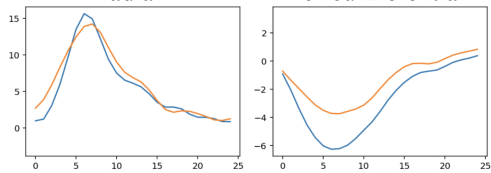


no prior



radial

circumferential



endocardium
epicardium