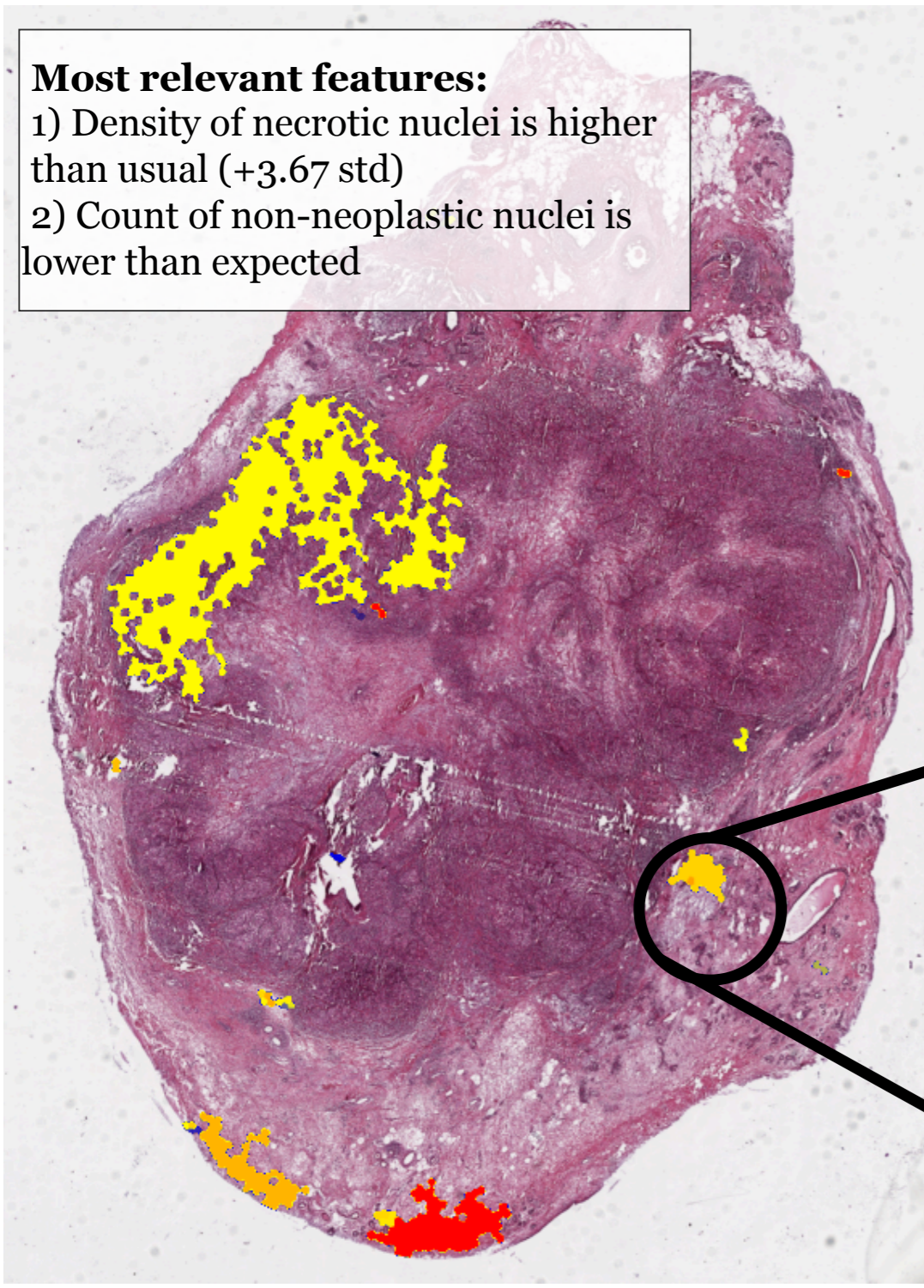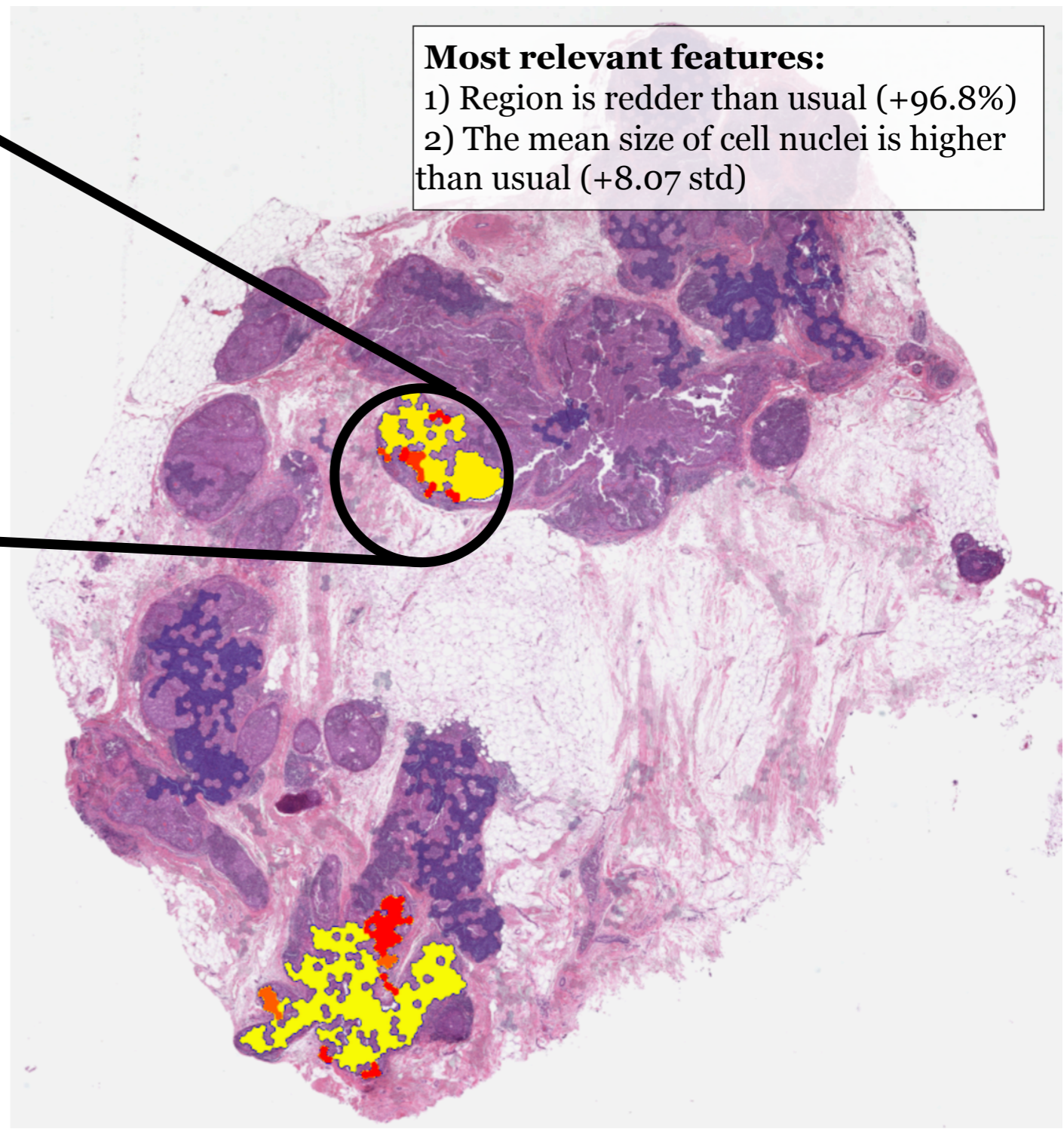
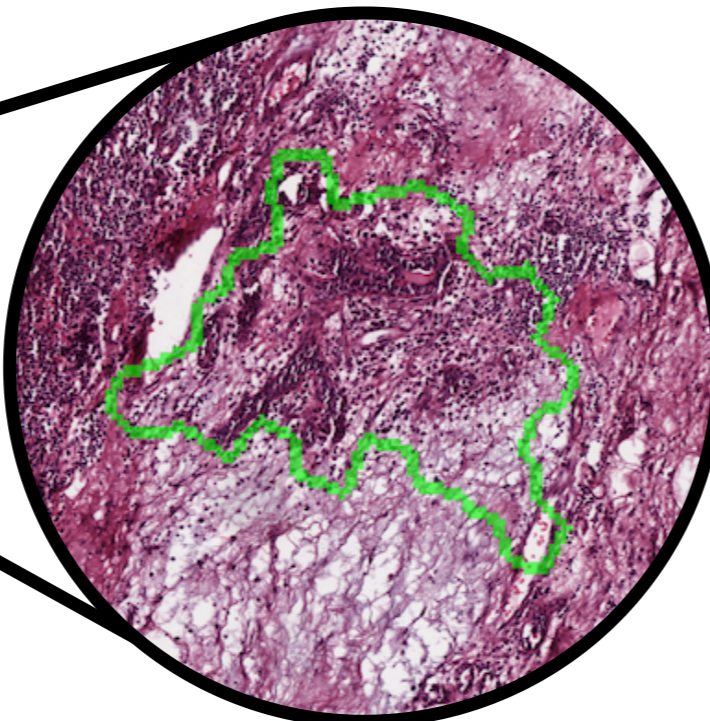
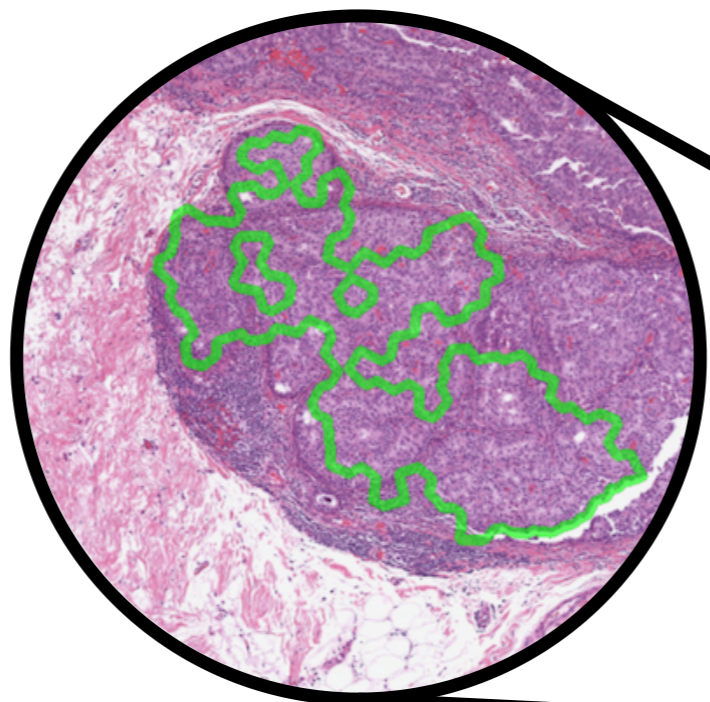


Most relevant features:
1) Density of necrotic nuclei is higher than usual (+3.67 std)
2) Count of non-neoplastic nuclei is lower than expected



Most relevant features:
1) Region is redder than usual (+96.8%)
2) The mean size of cell nuclei is higher than usual (+8.07 std)