

Radiology Report

"Right thyroid lobe sizes increased.Mild scoliosis with left opening is observed in the thoracic region.", Calcific atheromatous plaques in coronary arteries. **Slight increase in heart size.** Several reactive-looking lymph nodes in the mediastinal area. Minimal bronchiectatic changes and mild peribronchial thickness increases. Sequelae of fibrotic densities in both lungs.

(?i)(heart\s+size\s+increased|cardiomeg[a-z]+)

Template & rule-based

Annotate + Training

Report CLS model

Supervised

You are a medical report analyzer. Determine the presence (1) or absence (0) of each condition.

Zero-shot



Scaling Data



Manually Annotate

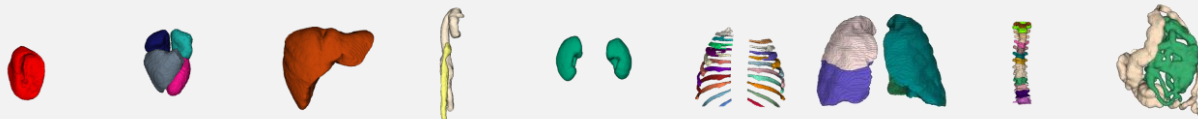
Annotate + Training

Segmentation model

Supervised

Universal Segmentation Model (TotalSegmentator)

Zero-shot



Anatomical Segmentation

Scaling Supervision