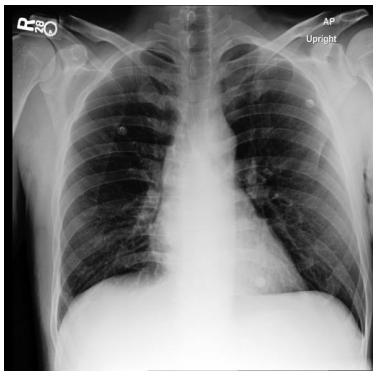


Qualitative example of report generation task

Input Prompt



Please generate a radiology report for this scan
<image-1>

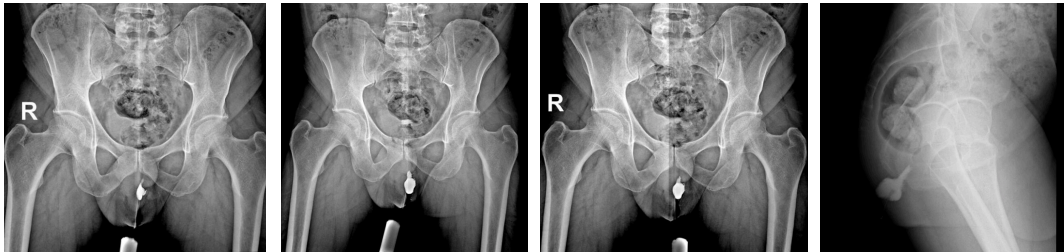
Reference Report

Findings: The lungs are clear without focal consolidation. No pleural effusion or pneumothorax is seen. The cardiac and mediastinal silhouettes are unremarkable.
Impression: No acute cardiopulmonary process.

RadFM Prediction

Findings : The lungs are clear without focal consolidation. No pleural effusion or pneumothorax is seen. The cardiac and mediastinal silhouettes are unremarkable.
Impression: No acute cardiopulmonary process

Input Prompt



<image-1> <image-2> <image-3> <image-4>

<image-1> <image-2> Patient Data Age: 40 years
Gender: Male Perianal purulent discharge and tenderness. Please caption this scan with finding and impression. <image-3> <image-4>

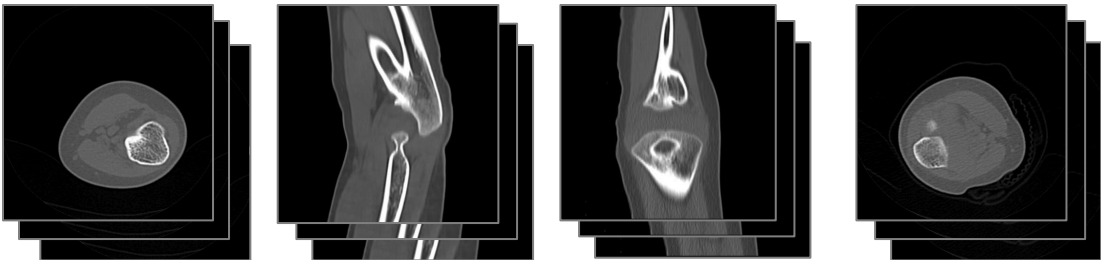
Reference Report

'Finding: Injection of contrast via the orifice of purulent discharge showed opacification of the left perianal abscess.
No evidence of obvious contrast extravasation into the anal canal or rectum.
Impression: Left perianal abscess with no evidence of contrast extravasation into the anal canal or rectum

RadFM Prediction

Findings : The lungs are clear without focal consolidation. No pleural effusion or pneumothorax is seen. The cardiac and mediastinal silhouettes are unremarkable.
Impression: No acute cardiopulmonary process

Input Prompt



<image-1> <image-2> <image-3> <image-4>

Patient Data Age: 4 years Gender: Male Both forearms are Fixed in a pronated position since birth. Describe the finding and impression of the medical image you see.
. <image-1> <image-2> <image-3> <image-4>

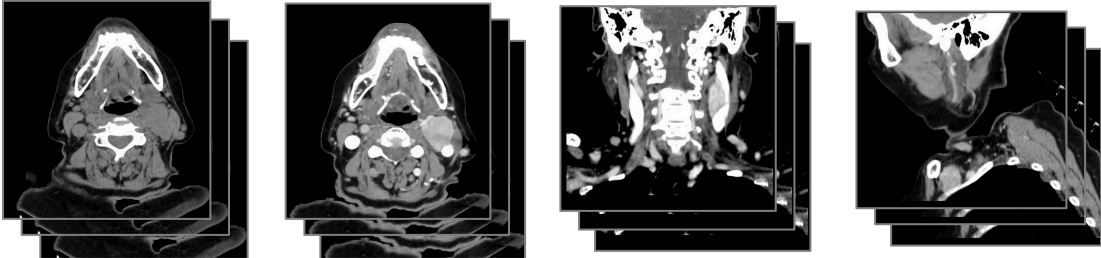
Reference Report

'Finding: Injection of contrast via the orifice of purulent discharge showed opacification of the left perianal abscess.
No evidence of obvious contrast extravasation into the anal canal or rectum.
Impression: Left perianal abscess with no evidence of contrast extravasation into the anal canal or rectum

RadFM Prediction

Findings : The lungs are clear without focal consolidation. No pleural effusion or pneumothorax is seen. The cardiac and mediastinal silhouettes are unremarkable.
Impression: No acute cardiopulmonary process

Input Prompt



<image-1> <image-2> <image-3> <image-4>

Patient Data Age: Patient Data Age: 65 years
Gender: Female Painless mass of the left upper neck. Please caption this scan with finding and impression.
. <image-1> <image-2> <image-3> <image-4>

Reference Report

Findings: Well-circumscribed vividly enhancing left upper cervical mass in the carotid space, splaying the internal and external carotid arteries (lyre sign).

RadFM Prediction

[Finding: A large well-defined vividly enhancing soft tissue mass of the left carotid space splaying the internal and external carotid arteries (the lyre sign), isodense to the muscles.
Impression: Large well-defined vividly enhancing soft tissue mass of the left carotid space, splaying the internal and external carotid arteries