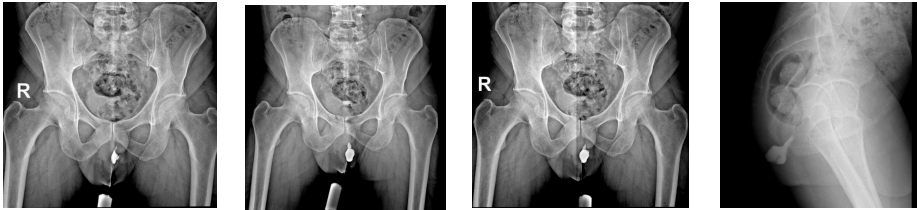


Qualitative examples of report generation task

Input Prompt

<image-1> <image-2> Patient Data Age: 40 years Gender: Male Perianal purulent discharge and tenderness. Please caption this scan with finding and impression. <image-3> <image-4>



<image-1> <image-2> <image-3> <image-4>

RadFM Prediction

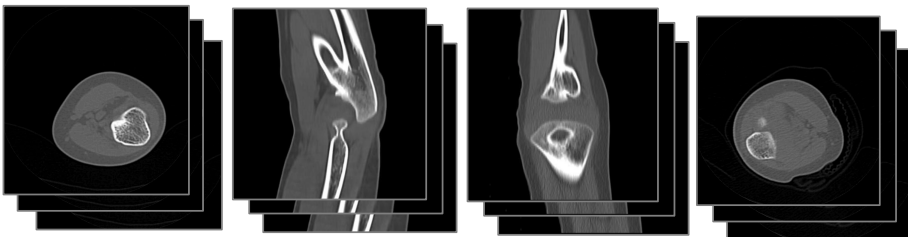
Finding: Injection of contrast via the orifice of purulent discharge showed opacification of the perianal abscess. No evidence of obvious contrast extravasation into the anal canal or rectum is seen.
Impression: Opacification of the perianal abscess. No evidence of contrast extravasation into the anal canal or rectum.

Reference Report

Finding: Injection of contrast via the orifice of purulent discharge showed opacification of the left perianal abscess. No evidence of obvious contrast extravasation into the anal canal or rectum.
Impression: Left perianal abscess with no evidence of contrast extravasation into the anal canal or rectum

Input Prompt

Patient Data Age: 4 years Gender: Male Both forearms are Fixed in a pronated position since birth. Describe the finding and impression of the medical image you see. <image-1> <image-2> <image-3> <image-4>



<image-1> <image-2> <image-3> <image-4>

RadFM Prediction

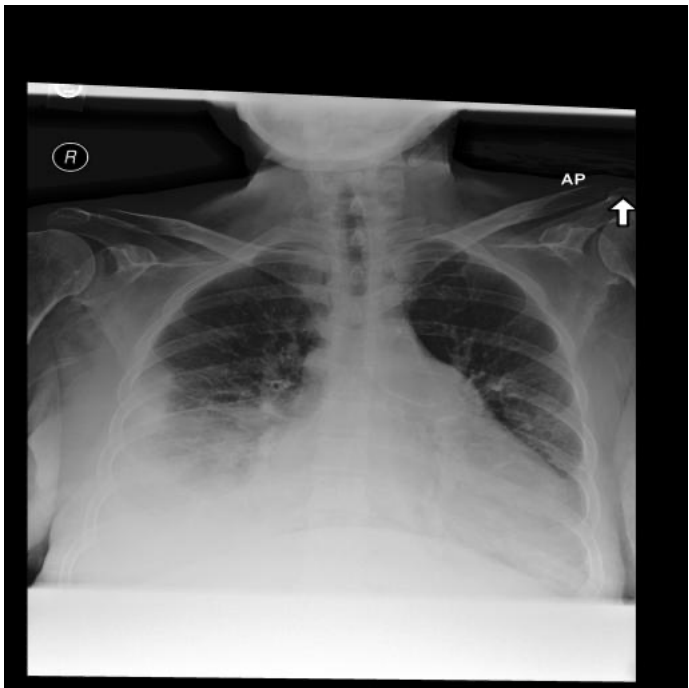Finding: Bilateral bony fusion at the proximal third of the radius and ulna. Hypoplastic with posterior dislocation of the radial head.
Impression: Bilateral bony fusion with hypoplastic radius and ulna. Posterior dislocation of the radial head.

Reference Report

Finding: Bilateral proximal radioulnar bony fusion of length __. Hypoplastic with posterior dislocation of the radial heads.
Impression: Bilateral proximal radioulnar bony fusion with associated hypoplastic posterior dislocation of the radial heads.

Input Prompt

Please generate a radiology report for this scan <image-1>



<image-1>

RadFM Prediction

Findings: The heart is mildly enlarged. There is mild unfolding and calcification along the aorta. The mediastinal and hilar contours appear unchanged. There is similar moderate relative elevation of the right hemidiaphragm compared to the left. There is no pleural effusion or pneumothorax. The lungs appear clear. Mild degenerative changes are similar along the thoracic spine.
Impression: No evidence of acute disease.

Reference Report

Findings: The heart size is moderately enlarged. The mediastinal silhouette and hilar contours are unchanged. A moderate to large right-sided pleural effusion is slightly increased in volume compared to prior examination with collapse of much of the right lower lobe and right middle lobe. There is also some consolidation at the base of the right upper lobe which could be due to compressive atelectasis. There is no left effusion. The upper lung zones appear clear. There is no pneumothorax.
Impression: Slightly increased moderate to large right-sided pleural effusion with collapse of much of the right middle lobe and right lower lobe. Superimposed pneumonia cannot be excluded given the appropriate clinical circumstance