

5 Appendix

Supplementary Table 1: Classification accuracy across skin conditions when synthetic images are included in the training set

Trained on FST I/II + 32 synthetic images							
FST	Basal Cell Carcinoma	Folliculitis	Nematode Infection	Neutrophilic Dermatoses	Prurigo Nodularis	Psoriasis	Squamous Cell Carcinoma
<i>Fitzpatrick Images Only</i>							
III-IV	0.543, 188	0.600, 150	0.655, 139	0.345, 119	0.611, 95	0.531, 192	0.451, 193
V-VI	0.419, 31	0.475, 40	0.409, 44	0.174, 46	0.711, 38	0.792, 77	0.556, 63
<i>Psoriasis</i>							
III-IV	0.580, 188	0.533, 150	0.662, 139	0.395, 119	0.653, 95	0.510, 192	0.420, 193
V-VI	0.516, 31	0.475, 40	0.455, 44	0.283, 46	0.632, 38	0.857, 77	0.524, 63
<i>Neutrophilic Dermatoses</i>							
III-IV	0.569, 188	0.487, 150	0.655, 139	0.454, 119	0.653, 95	0.557, 192	0.456, 193
V-VI	0.516, 31	0.550, 40	0.386, 44	0.676, 37	0.684, 38	0.694, 85	0.429, 63
<i>Squamous Cell Carcinoma</i>							
III-IV	0.569, 188	0.493, 150	0.640, 139	0.294, 119	0.695, 95	0.531, 192	0.461, 193
V-VI	0.323, 31	0.475, 40	0.341, 44	0.174, 46	0.684, 38	0.694, 85	0.691, 55
Trained on FST V/VI + 32 synthetic images							
FST	Basal Cell Carcinoma	Folliculitis	Nematode Infection	Neutrophilic Dermatoses	Prurigo Nodularis	Psoriasis	Squamous Cell Carcinoma
<i>Fitzpatrick Images Only</i>							
I-II	0.664, 241	0.110, 127	0.704, 71	0.157, 185	0.314, 35	0.196, 337	0.236, 280
III-IV	0.681, 188	0.200, 150	0.640, 139	0.303, 119	0.442, 95	0.240, 192	0.394, 193
<i>Psoriasis</i>							
I-II	0.656, 241	0.173, 127	0.718, 71	0.119, 185	0.314, 35	0.466, 337	0.225, 280
III-IV	0.729, 188	0.247, 150	0.647, 139	0.294, 119	0.389, 95	0.401, 192	0.352, 193
<i>Neutrophilic Dermatoses</i>							
I-II	0.485, 241	0.094, 127	0.648, 71	0.525, 177	0.286, 35	0.252, 345	0.257, 280
III-IV	0.660, 188	0.227, 150	0.619, 139	0.521, 119	0.463, 95	0.276, 192	0.378, 193
<i>Squamous Cell Carcinoma</i>							
I-II	0.307, 241	0.165, 127	0.775, 71	0.114, 185	0.371, 35	0.261, 345	0.511, 272
III-IV	0.505, 188	0.253, 150	0.691, 139	0.286, 119	0.421, 95	0.318, 192	0.446, 193

Supplementary Table 2: All text prompts used for synthetic image generation alongside the number of attempts with each prompt and the number of images selected for the study using that prompt.

All text prompts for DALL-E 2 generations		
Prompt: "An image of..."	attempts	# selected
... neutrophilic dermatoses on the leg of a very dark-skinned woman	2	3
... neutrophilic dermatoses on the shoulder of a dark-skinned woman	1	1
... neutrophilic dermatoses on the leg of a dark-skinned man	2	2
... neutrophilic dermatoses on the arm of a dark-skinned man	1	2
... neutrophilic dermatoses on the hand of a dark-skinned individual	1	2
... neutrophilic dermatoses on the arm of a dark-skinned individual	2	2
... neutrophilic dermatoses on the leg of a very dark-skinned woman	1	2
... neutrophilic dermatoses on the hand of a very dark-skinned woman	1	2
... neutrophilic dermatoses on the leg of a very dark-skinned man	2	2
... neutrophilic dermatoses on the arm of a very dark-skinned man	1	2

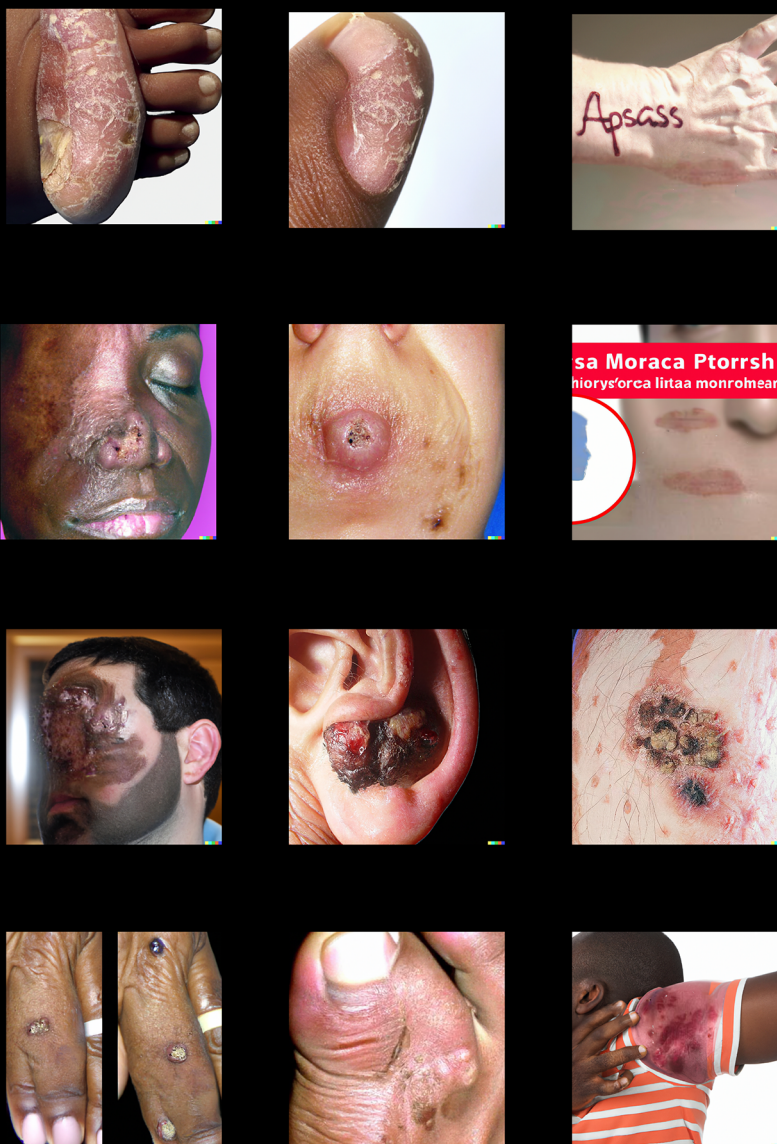
Table 2 continued from previous page

... neutrophilic dermatoses on the leg of a very dark-skinned individual	2	2
... neutrophilic dermatoses on the elbow of a very dark-skinned individual	1	2
... neutrophilic dermatoses on the foot of a dark-skinned man	1	2
... neutrophilic dermatoses on the neck of a dark-skinned man	2	2
... neutrophilic dermatoses on the arm of a very dark-skinned woman	1	2
... neutrophilic dermatoses on the leg of a very dark-skinned woman	1	2
... neutrophilic dermatoses on the neck of a light-skinned woman	1	2
... neutrophilic dermatoses on the face of a light-skinned woman	2	2
... neutrophilic dermatoses on the hand of a light-skinned individual	1	2
... neutrophilic dermatoses on the arm of a light-skinned individual	2	2
... neutrophilic dermatoses on the arm of a light-skinned individual	2	2
... neutrophilic dermatoses on the hand of a light-skinned individual	2	2
... neutrophilic dermatoses on the shoulder of a light-skinned man	2	2
... neutrophilic dermatoses on the face of a light-skinned man	1	2
... neutrophilic dermatoses on the foot of a light-skinned woman	2	2
... neutrophilic dermatoses on the feet of a light-skinned woman	2	2
... neutrophilic dermatoses on the shoulder of a very light-skinned individual	2	2
... neutrophilic dermatoses on the face of a very light-skinned individual	1	2
... neutrophilic dermatoses on the back of a very light-skinned man	1	2
... neutrophilic dermatoses on the thigh of a very light-skinned man	2	2
... neutrophilic dermatoses on the arm of a light-skinned woman	1	2
... neutrophilic dermatoses on the leg of a light-skinned woman	1	2
... psoriasis on the back of a dark-skinned man	1	2
... psoriasis on the leg of a dark-skinned woman	1	2
... psoriasis on the thigh of a very dark-skinned man	1	2
... psoriasis on the arm of a very dark-skinned man	2	2
... psoriasis on the foot of a very dark-skinned woman	1	2
... psoriasis on the foot of a very dark-skinned woman	2	2
... psoriasis on the back of a dark-skinned individual	3	2
... psoriasis on the arm of a dark-skinned individual	2	1
... psoriasis under the knee of a dark-skinned individual	1	1
... psoriasis on the legs of a very dark-skinned woman	1	2
... psoriasis on the arms of a very dark-skinned woman	1	2
... psoriasis on the cheek of a dark-skinned man	1	2
... psoriasis on the face of a dark-skinned man	1	2
... psoriasis on the foot of a very dark-skinned man	2	1
... psoriasis on the hand of a very dark-skinned man	2	3
... psoriasis on the knee of a dark-skinned individual	1	3
... psoriasis on the back of a dark-skinned individual	1	1
... psoriasis on the fingers of a light-skinned individual	2	2
... psoriasis on the fingernails of a light-skinned individual	1	2
... psoriasis on the fingernails of a light-skinned individual	1	2
... psoriasis on the fingernails of a light-skinned individual	1	2
... psoriasis on the knee of a light-skinned woman	2	3
... psoriasis on the back of a light-skinned woman	1	1
... psoriasis on the arm of a light-skinned woman	2	1
... psoriasis on the leg of a light-skinned woman	1	3
... psoriasis on the legs of a light-skinned man	1	2
... psoriasis on the elbow of a light-skinned man	1	2
... psoriasis on the fingernails of a light-skinned individual	1	3
... psoriasis on the hand of a light-skinned individual	1	1
... psoriasis on the leg of a very light-skinned woman	1	2
... psoriasis on the arm of a very light-skinned woman	1	2
... psoriasis on the legs of a light-skinned man	1	2
... psoriasis on the hands of a light-skinned man	2	2
... squamous cell carcinoma on the nose of a light-skinned woman	1	2
... squamous cell carcinoma on the face of a light-skinned woman	1	2
... squamous cell carcinoma on the skin of a light-skinned individual	1	2

Table 2 continued from previous page

... squamous cell carcinoma on the skin of a light-skinned individual	1	2
... squamous cell carcinoma on the neck of a light-skinned individual	1	2
... squamous cell carcinoma on the arm of a light-skinned individual	1	2
... squamous cell carcinoma on the leg of a very light-skinned man	1	2
... squamous cell carcinoma on the arm of a very light-skinned man	1	2
... squamous cell carcinoma on the shoulder of a very light-skinned woman	1	2
... squamous cell carcinoma on the back of a very light-skinned woman	1	2
... squamous cell carcinoma on the neck of a very light-skinned individual	2	2
... squamous cell carcinoma on the skin of a very light-skinned individual	1	2
... squamous cell carcinoma on the skin of a very light-skinned man	1	2
... squamous cell carcinoma on the shoulder of a very light-skinned man	2	2
... squamous cell carcinoma under the ear of a light-skinned individual	1	3
... squamous cell carcinoma under the ear of a light-skinned individual	1	1
... squamous cell carcinoma on the knee of a dark-skinned individual	1	1
... squamous cell carcinoma on the knee of a dark-skinned individual	1	3
... squamous cell carcinoma on the nose of a dark-skinned man	1	2
... squamous cell carcinoma on the cheek of a dark-skinned man	1	2
... squamous cell carcinoma on the hands of a dark-skinned woman	2	3
... squamous cell carcinoma on the leg of a dark-skinned woman	1	1
... squamous cell carcinoma on the arm of a dark-skinned individual	1	2
... squamous cell carcinoma on the leg of a dark-skinned individual	1	2
... squamous cell carcinoma on the elbow of a dark-skinned man	1	3
... squamous cell carcinoma on the knee of a dark-skinned man	1	1
... squamous cell carcinoma on the shoulder of a very dark-skinned woman	1	2
... squamous cell carcinoma on the legs of a very dark-skinned woman	2	2
... squamous cell carcinoma on the leg of a dark-skinned man	1	2
... squamous cell carcinoma on the arm of a dark-skinned man	1	2
... squamous cell carcinoma on the neck of a very dark-skinned woman	1	2
... squamous cell carcinoma on the leg of a very dark-skinned woman	1	2

Examples of DALL-E 2 images not selected for inclusion in a training set



Supplementary Figure 1: **Examples of generated images that were not chosen for inclusion in a training set.** Images were not selected for a variety of reasons, including abnormal changes to anatomy, introduction of irregular artifacts, and misplacement of the disease pathology.