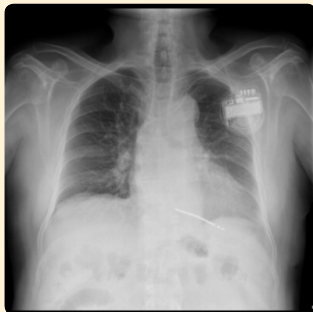

Lungs and Airways:
- Clear lungs

Pleura:
- No pleural effusions

Hila and Mediastinum:
- Mediastinal and hilar contours appear stable



Others

Lungs and Airways

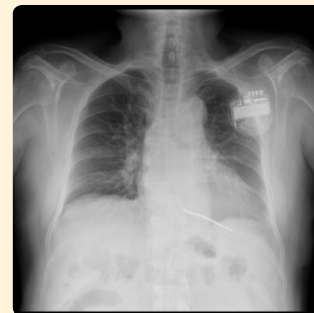
Low lung volumes

Pleura

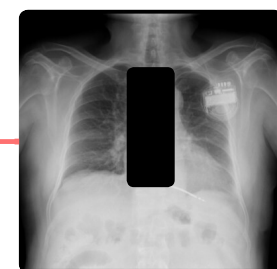
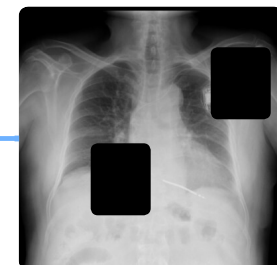
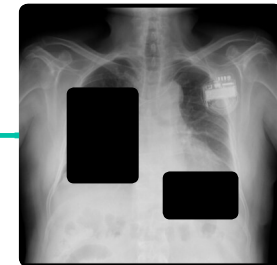
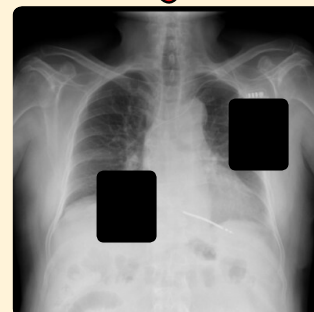
Small left pleural effusion

Hila and Mediastinum

Mediastinal and hilar contours are stable



Contrasted



Category-Wise Contrastive Decoding