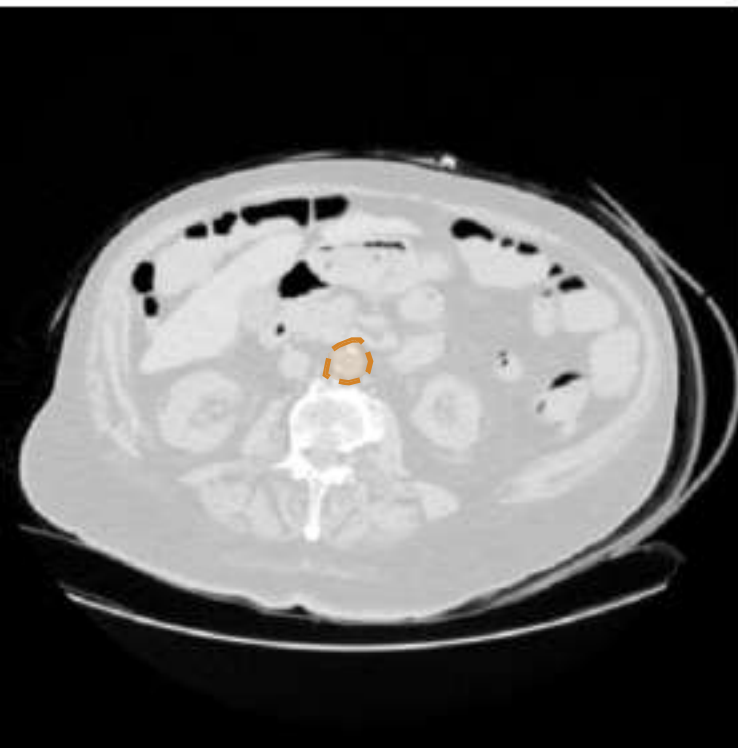
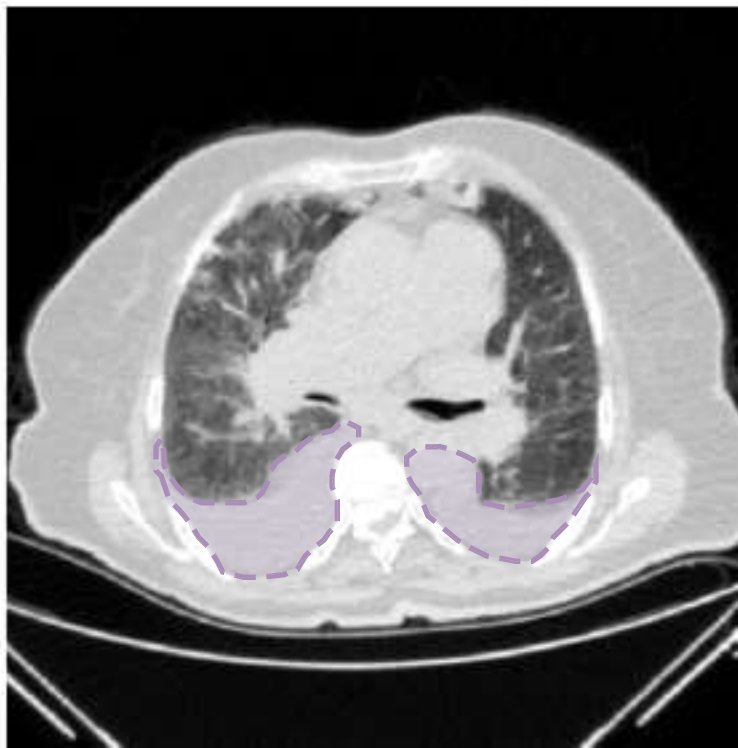


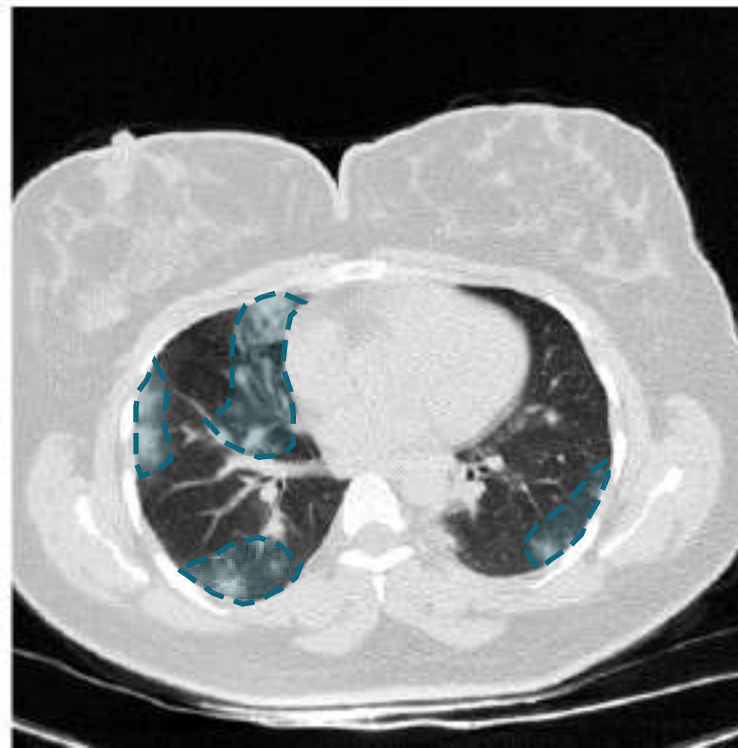
Arterial Wall Calcific.



Pleural Effusion



Lung Opacity



Cardiomegaly

