

APPENDIX

MORE QUALITATIVE EXAMPLES OF WEAKLY SUPERVISED LESION LOCALIZATION

Below, we visualize weakly supervised localization for two COVID-19 positive patients, and two common pneumonia patients. The index at the bottom left corner of each image refers to the slice index in original CT scans. The images with green stars at the top right corner are the ground truth slices containing lesions. The slices within the orange box are localized using the GCN diagnosis model.

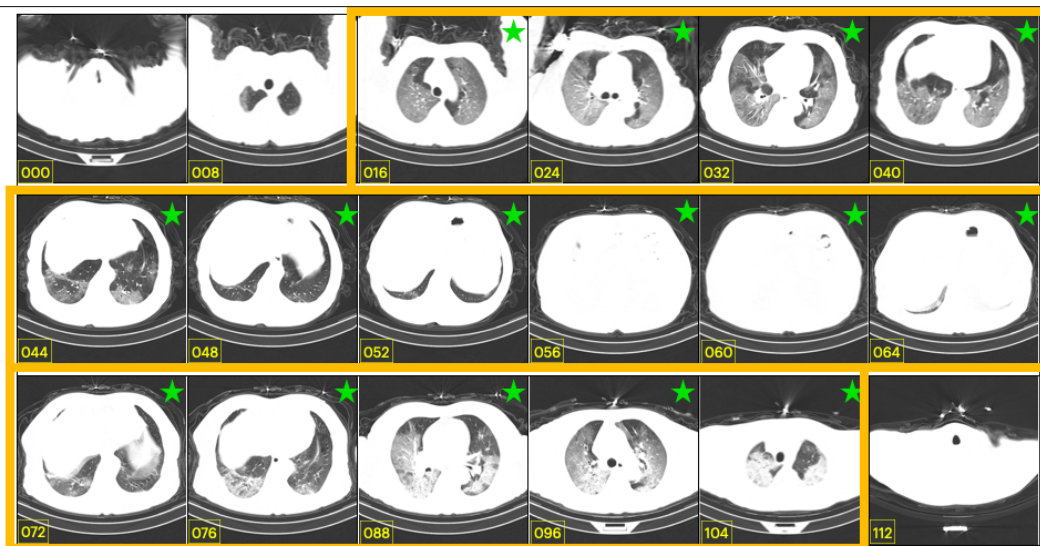


Figure 1: COVID-19 Positive Patient 1.

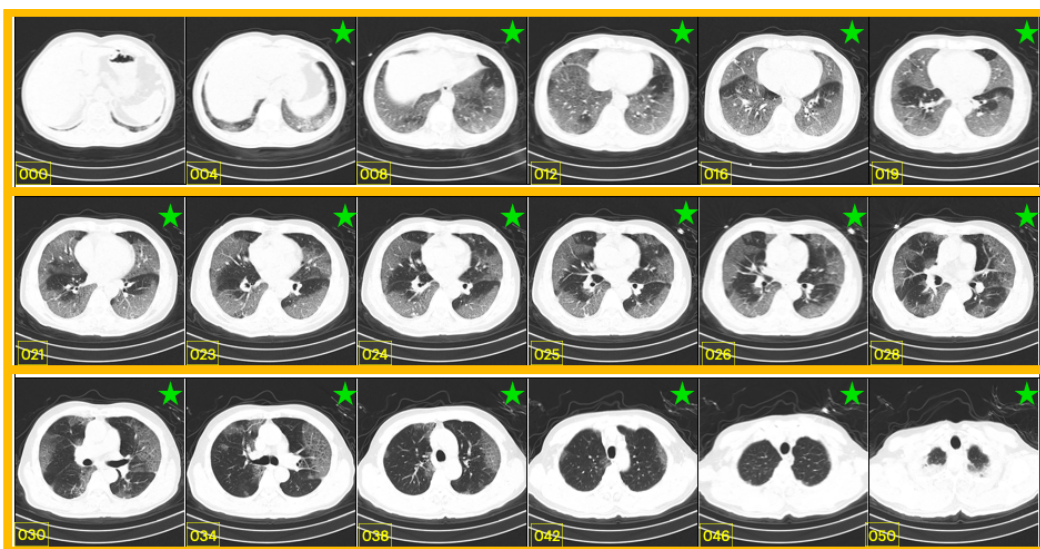


Figure 2: COVID-19 Positive Patient 2.

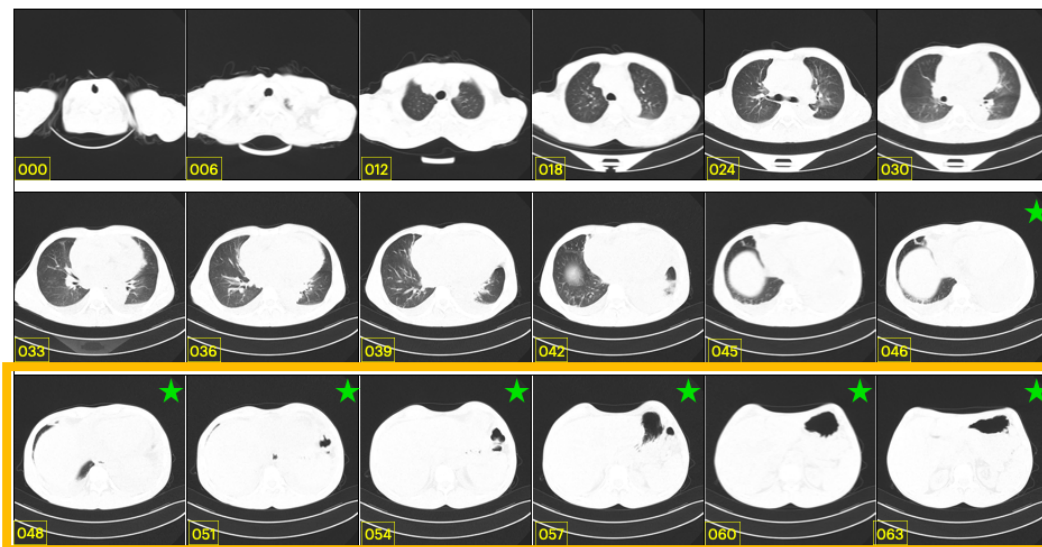


Figure 3: Common Pneumonia Patient 1.

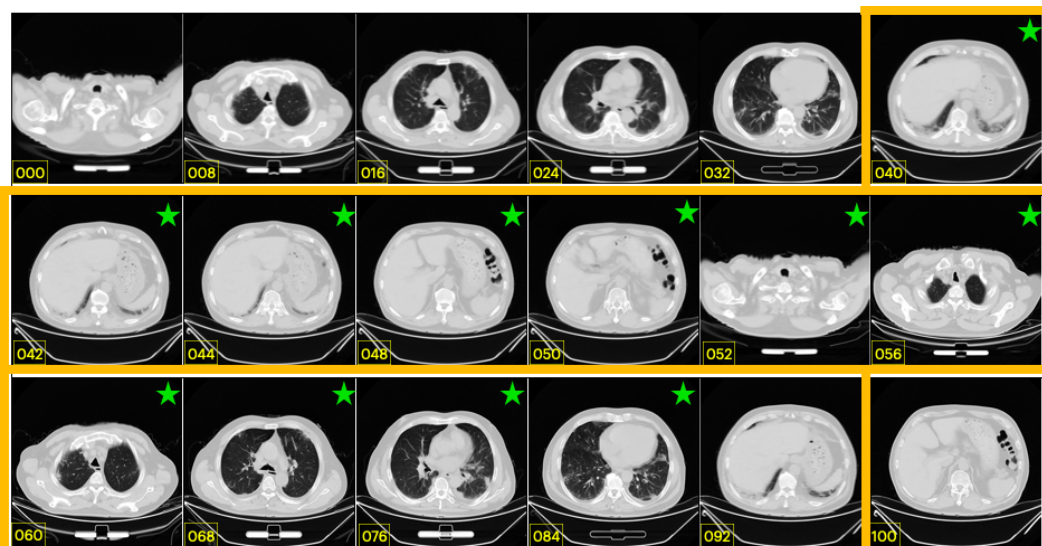


Figure 4: Common Pneumonia Patient 2.