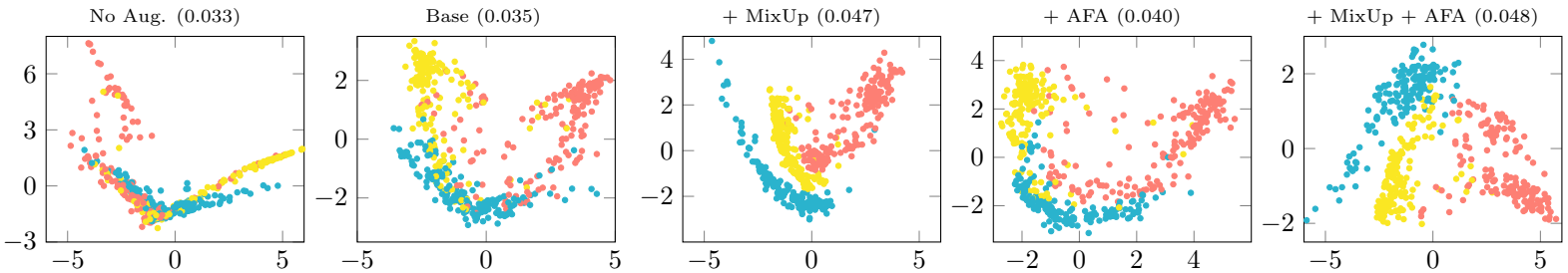


● Background ● Left Ventricle ● Myocardium ● Right Ventricle



● Background ● Transition Zone ● Peripheral Zone