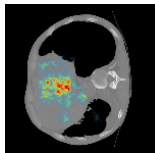
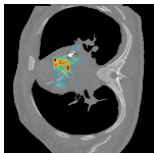


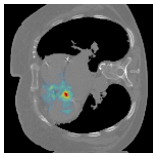
Reduced RV



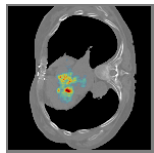
Reduced LV



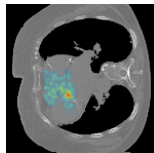
Pulm. Hypert.



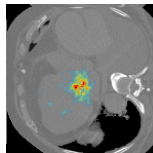
Atrial Enlarg.



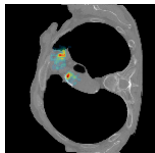
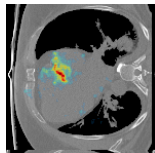
Ventri. Enlarg.



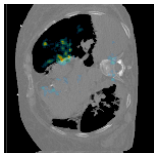
LA Pressure



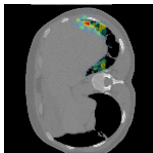
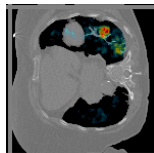
RA Pressure



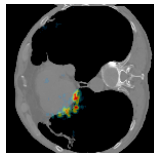
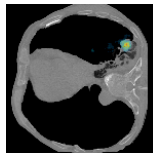
Med. Material



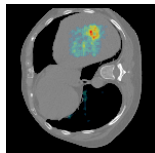
Bronchiectasis

Pulm. fibro.
sequela

Lung opacity

Inter. septal
thickening

Consolidation



Atelectasis