

Vispi: Automatic Visual Perception and Interpretation of Chest X-rays

Xin Li¹, Rui Cao², Dongxiao Zhu¹

¹Department of Computer Science, Wayne State University, USA

²School of Information Science and Technology, Northwest University, China



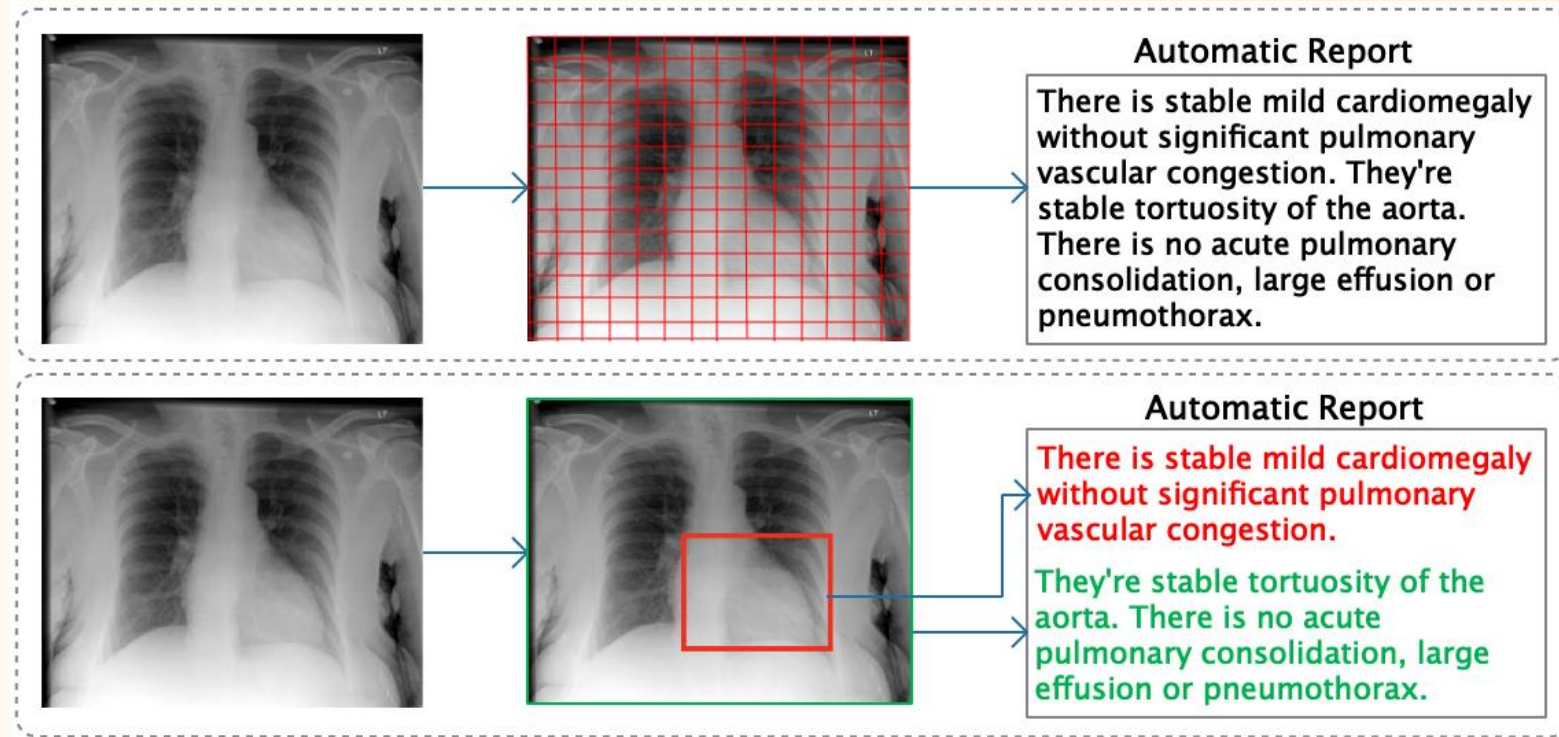
Introduction

- X-ray is a widely used medical imaging technique in clinics for diagnosis and treatment of thoracic diseases.
- Medical image interpretation, including both disease annotation and report writing, is a laborious routine for radiologists.
- To release radiologists from their excessive workload, it is desirable to implement a medical image interpretation system that automates the visual perception and cognition process and generates draft reports for radiologists to review, revise and finalize.

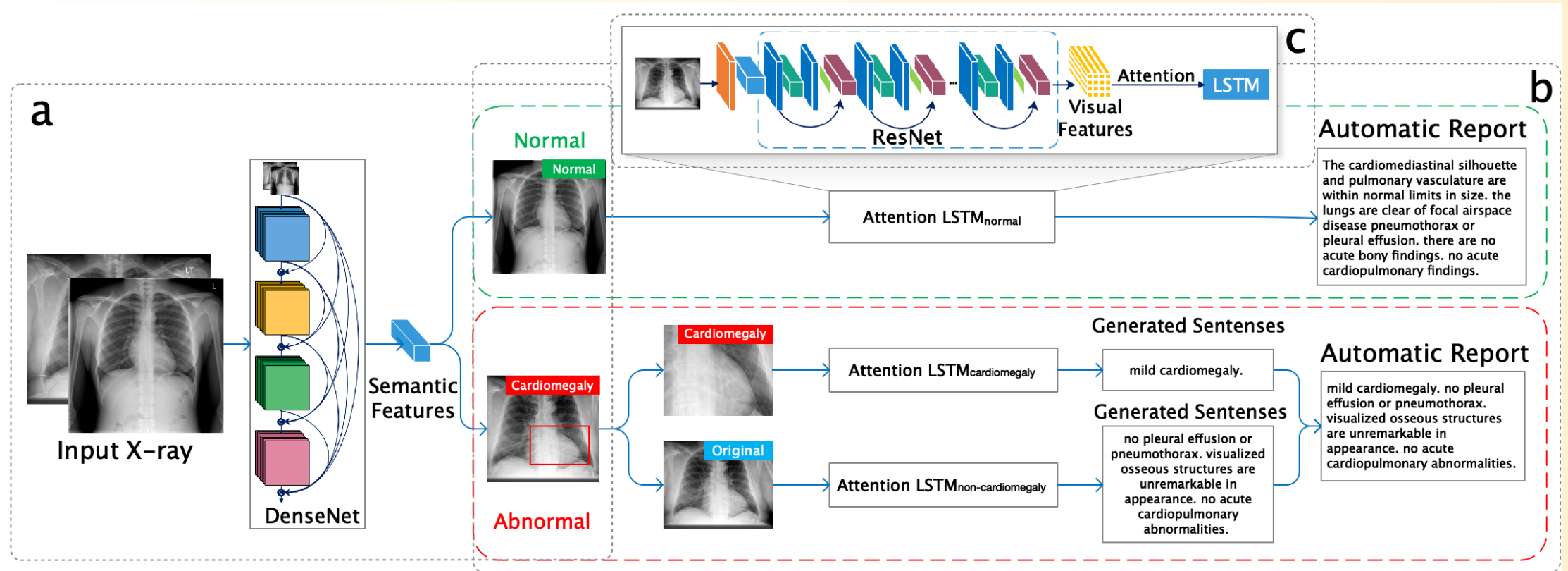


Comparison of Previous Approach and Ours

- Previous
 - Generate report directly
- Ours
 - Predict disease
 - Generate report



Our Solution



Experiments and Results

- Dataset: IU Chest X-ray Collection

Model	CIDEr	ROUGE	BLEU-1	BLEU-2	BLEU-3	BLEU-4
CNN-RNN (Vinyals et al., 2015)*	0.294	0.306	0.216	0.124	0.087	0.066
LRCN (Donahue et al., 2015)*	0.284	0.305	0.223	0.128	0.089	0.067
AdaAtt (Lu et al., 2017)*	0.295	0.308	0.220	0.127	0.089	0.068
Att2in (Rennie et al., 2017)*	0.297	0.308	0.224	0.129	0.089	0.068
CoAtt (Jing et al., 2017)*	0.277	0.369	0.455	0.288	0.205	0.154
HRGR (Li et al., 2018)*	0.343	0.322	0.438	0.298	0.208	0.151
MRA (Xue et al., 2018) ⁺	N\A	0.366	0.464	0.358	0.270	0.195
Vispi	0.553	0.371	0.419	0.280	0.201	0.150


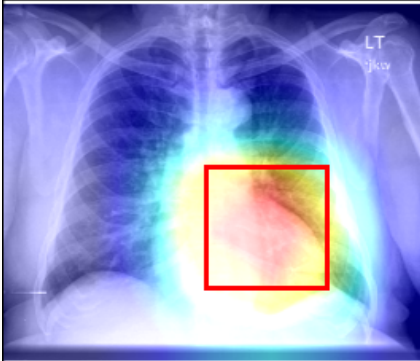
Evaluation of Automatic Medical Image Reports

Disease	Ate	Cardio	Effusion	Infil	Mass	Nodule	Pneum	Pneumox	Average
TieNet*	0.744	0.847	0.899	0.718	0.823	0.658	0.731	0.709	0.757
Vispi	0.806	0.856	0.919	0.610	0.984	0.758	0.764	0.733	0.804

Evaluation of Disease Classification



Illustration of two cases

Sample Case	Annotation	Manual Report	Automatic Report
	Normal	the heart size and cardiomediastinal silhouette are within normal limits. pulmonary vasculature appears normal. There is no focal air space consolidation.no pleural effusion or pneumothorax.	the cardiomediastinal silhouette and pulmonary vasculature are within normal limits in size. the lungs are clear of focal airspace disease pneumothorax or pleural effusion. there are no acute bony findings. no acute cardiopulmonary findings.
	Cardiomegaly	mild cardiomegaly. mild unfolding of the thoracic aorta. no focal air space opacity. no pleural effusion or pneumothorax. visualized osseous structures are unremarkable in appearance. otherwise no acute cardiopulmonary abnormalities.	mild cardiomegaly. there is no focal consolidation. no pleural effusion or pneumothorax. there is no focal air space consolidation. no pleural effusion or pneumothorax. degenerative changes of the thoracic spine. no acute cardiopulmonary abnormality.



Thank you!





WAYNE STATE UNIVERSITY