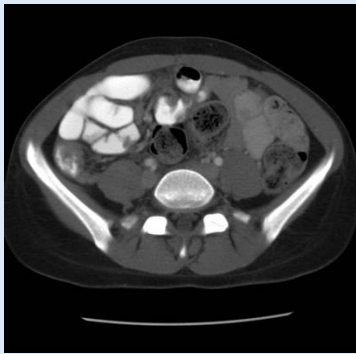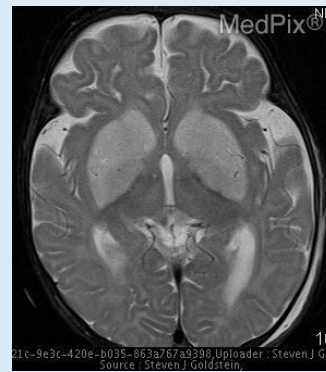


Question: Is there evidence of small bowel obstruction on this image?

Model Output: yes

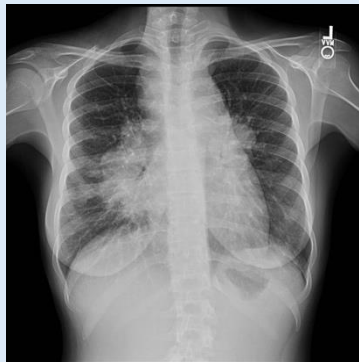Ground Truth: yes



Question: Are the brain gyri atrophied?

Model Output: no

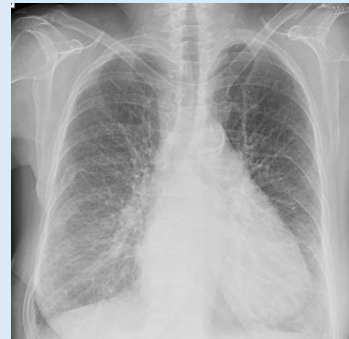Ground Truth: no



Question: What is this lucency amid densities in the right lung?

Model Output: bronchus

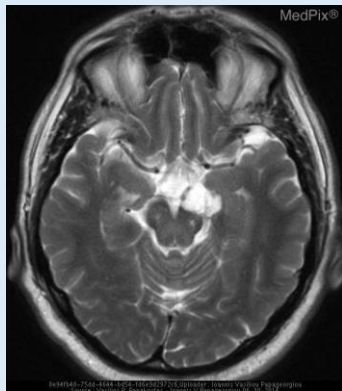
Ground Truth: bronchus



Question: Where is the pleural effusion located?

Model Output: right lung

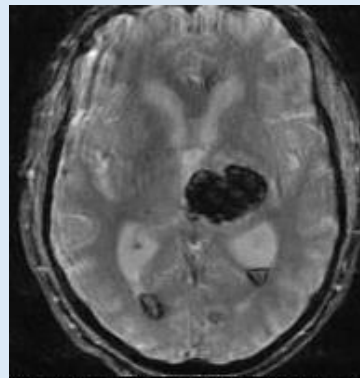
Ground Truth: right lung



Question: What type of imaging modality is used to acquire the above image?

Model Output: t2 weighted mri

Ground Truth: mri - t2 weighted



Question: What structures are located near the hemorrhage shown?

Model Output: left basal ganglia

Ground Truth: left thalamus and basal ganglia