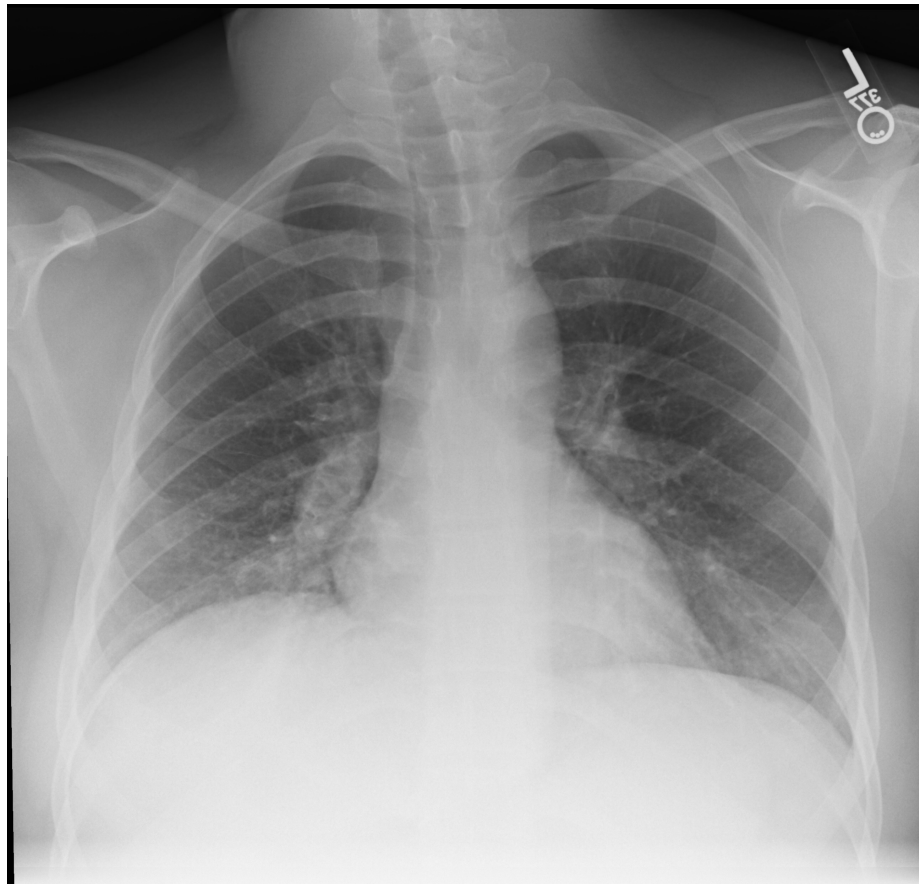


Radiologist's transcript

"no pneumothorax.  
cardiac silhouette  
normal. clear lungs."

Original Image



Generated Image

