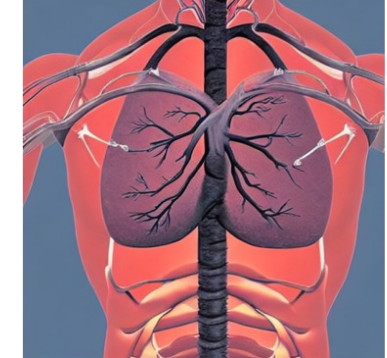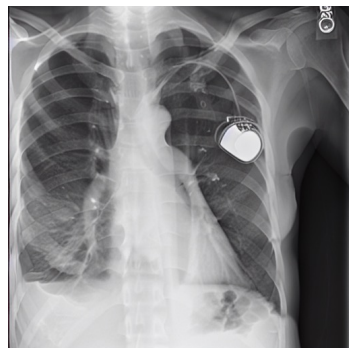


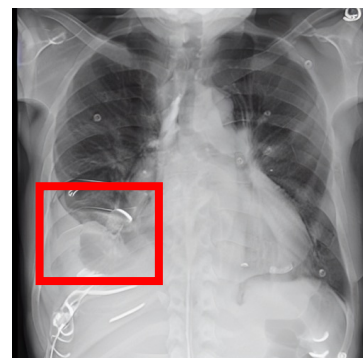
SD

"large ... and right  
basilar  
consolidation ...  
no acute osseous  
abnormality.



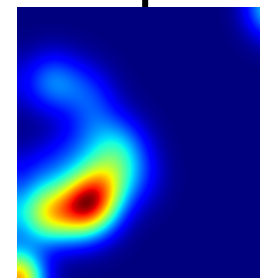
SD-CXR

"large ... and right  
basilar  
consolidation ...  
no acute osseous  
abnormality.

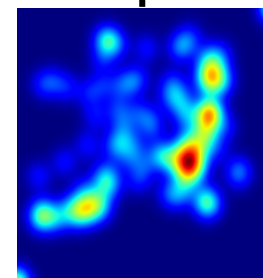


GazeDiff

"large ... and right  
basilar  
consolidation ...  
no acute osseous  
abnormality.



Focal HVA



Global HVA