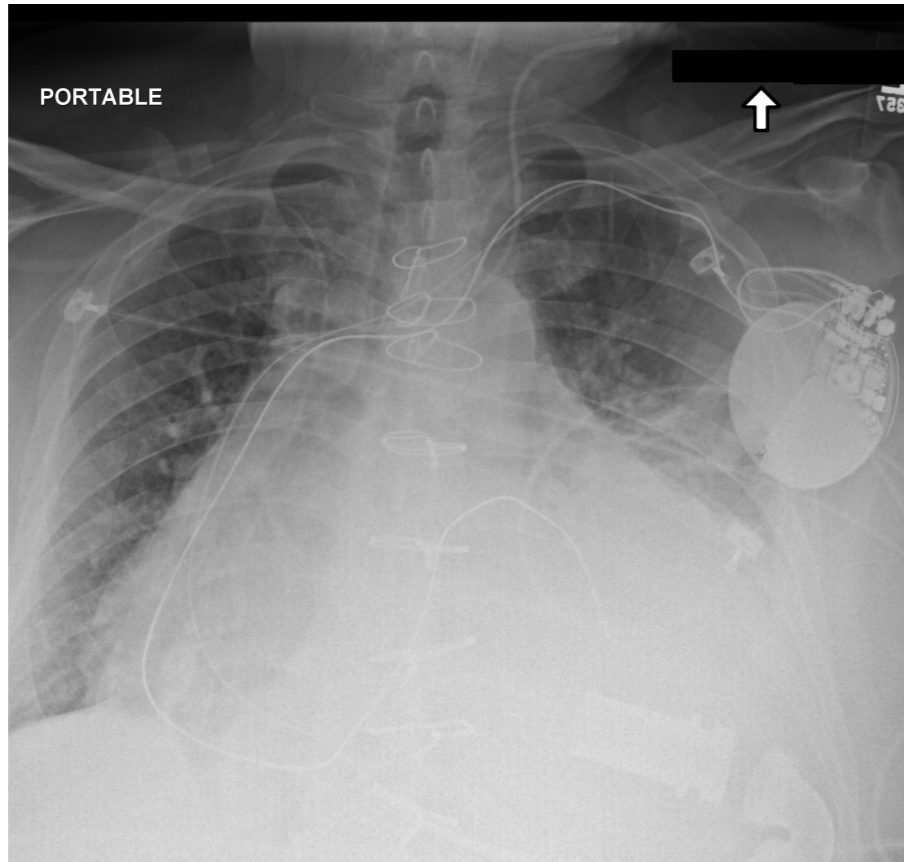


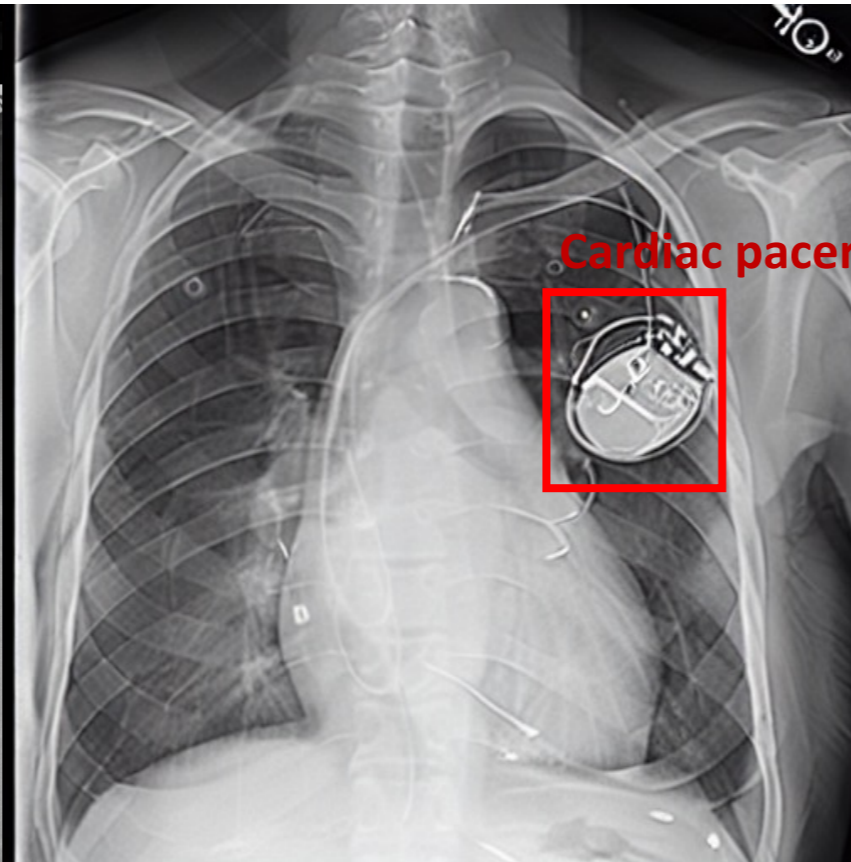
Radiologist's transcript

"left ij catheter is in the svc. right picc line is at the cavoatrial junction. there is a left ventricular assist device. **cardiac pacer** is noted with leads in the **right ventricle and coronary sinus**. there is moderate to severe cardiomegaly. mild diffuse hazy opacity likely represents pulmonary edema. there is left basilar atelectasis or consolidation. no pneumothorax. no acute osseous abnormality."

Original Image



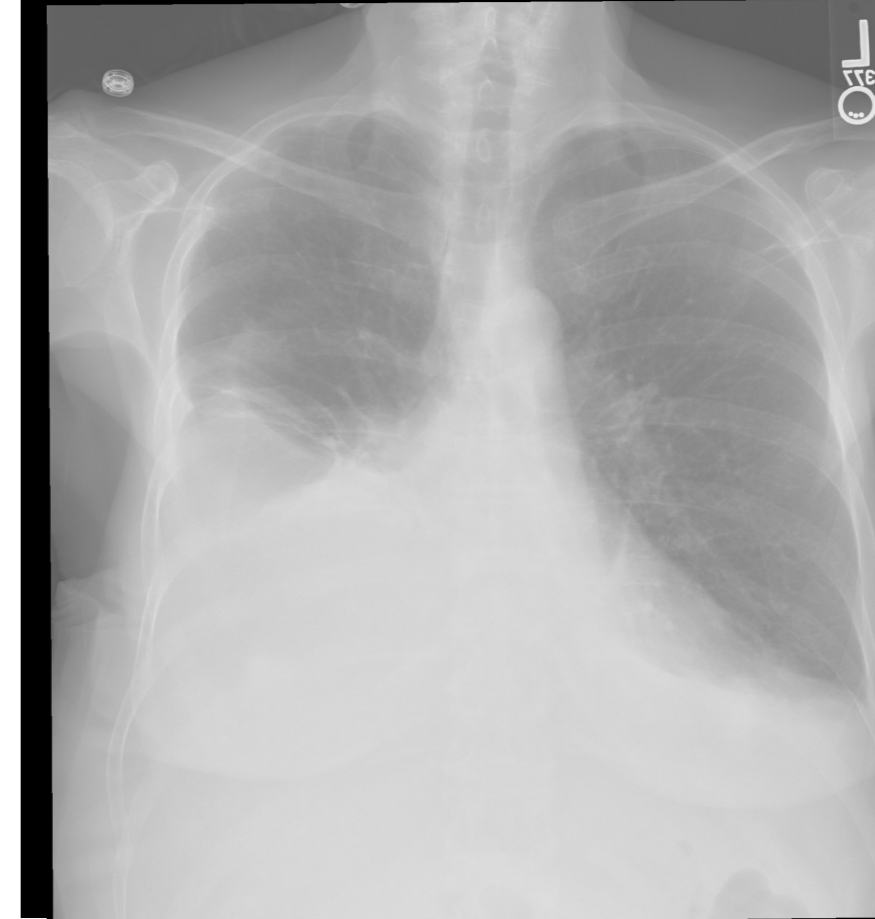
Generated Image



Radiologist's transcript

"large right pleural effusion with patchy ground-glass abnormality in the right upper lobe and **right basilar consolidation** versus multisegmental atelectasis, mass not excluded. left basilar subsegmental atelectasis. heart size appears within normal limits although the right cardiac border is obscured. no pneumothorax. no acute osseous abnormality."

Original Image



Generated Image

