Automated Multibeat Tissue Doppler Echocardiography Analysis Using Deep Neural Networks

Elisabeth Lane[1] ELISABETH.LANE@UWL.AC.UK
Jevgeni Jevsikov[1] JEVGENI.JEVSIKOV@UWL.AC.UK
Niti Dhutia[2] NITIDHUTIA@GMAIL.COM
Matthew J Shun-shin[3] M@SHUN-SHIN.COM
Darrel P Francis[3] DARREL@DRFRANCIS.ORG
Massoud Zolgharni[1,3] MASSOUD@ZOLGHARNI.COM
[1] *School of Computing and Engineering, University of West London, London, United Kingdom*
[2] *New York University, Abu Dhabi*
[3] *National Heart and Lung Institute, Imperial College, London, United Kingdom*

Editors: Under Review for MIDL 2022

Abstract

Tissue Doppler Imaging is an essential echocardiographic technique for the non-invasive assessment of myocardial blood velocity. Interpretation by trained experts is time-consuming and disruptive to workflow. This study presents an automated deep learning model, trained and tested on Doppler strips of arbitrary length, capable of rapid beat detection and Cartesian coordinate localisation of peak velocities with accuracy indistinguishable from human experts, but with greater speed.

Keywords: Cardiac imaging, Tissue Doppler Echocardiography, Deep learning

1. Introduction

Tissue Doppler imaging (TDI) is a relatively new echocardiographic technique that uses Doppler principles to measure the velocity of myocardial motion. Clinical guidelines recommend averaging peak velocity measurements over a minimum of three consecutive beats (Nagueh et al., 2008). However, echocardiographers often select beats they consider an average representative sample which may contribute to test-retest variability, leading to diagnostic errors (Finegold et al., 2013). A reliable and objective automated system would save valuable resources for health services and has potential to improve patient outcomes by averaging measurements over more beats. By removing manual detection, specialists' time can be better spent acquiring more high-quality beats, reducing subjectivity and cost.

2. Method

TDI traces were acquired from 48 patients with a mean age of 64±11 years, from both the septal and lateral annuli. Information about the dataset and patient characteristics can be found in (Dhutia et al., 2017). Six recordings were acquired for each patient and reconstructed into a continuous Doppler strip with a resolution of 900 x 1300 pixels. Information about the reconstruction methods can be found in (Zolgharni et al., 2014). The dataset comprises 280 Doppler strips (5,327 beats). Annotations are from three expert clinicians; ground-truth labels for Model training and evaluation were calculated as the expert consensus. Additionally, for the purpose of investigating inter-observer variability, three additional networks were trained on individual expert labels, named Model-1, Model-2 and Model-3, respectively.

© 2021 E. Lane, J. Jevsikov, N. Dhutia, M.J. Shun-shin, D.P. Francis & M. Zolgharni.

The network architecture is two-fold:

A. Heartbeats are detected/isolated (without the need for ECG signal) as a ROI by the Mask R-CNN architecture with a ResNet101 backbone. Images are resized and zero padded to 1024x1024 pixels

B1-B3. ROI is cropped and resized to 192 x 192 pixels and input to a convolutional heatmap regression model to predict Cartesian coordinates for systolic and diastolic peak velocities (S', E' and A'), as shown in Figure 1.

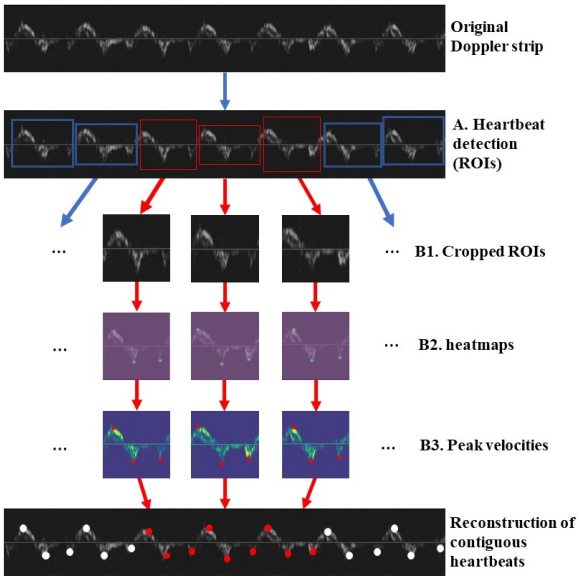

Figure 1: Illustration of the entire pipeline

3. Results and Discussion

Computation time for manual peak velocity annotations by human experts, compared to the automated model, was calculated over an average sample of 25 heartbeats; 4.76 seconds and 0.18 milliseconds, respectively. Cartesian coordinates in pixels were converted into Velocity measurements in cm/s.

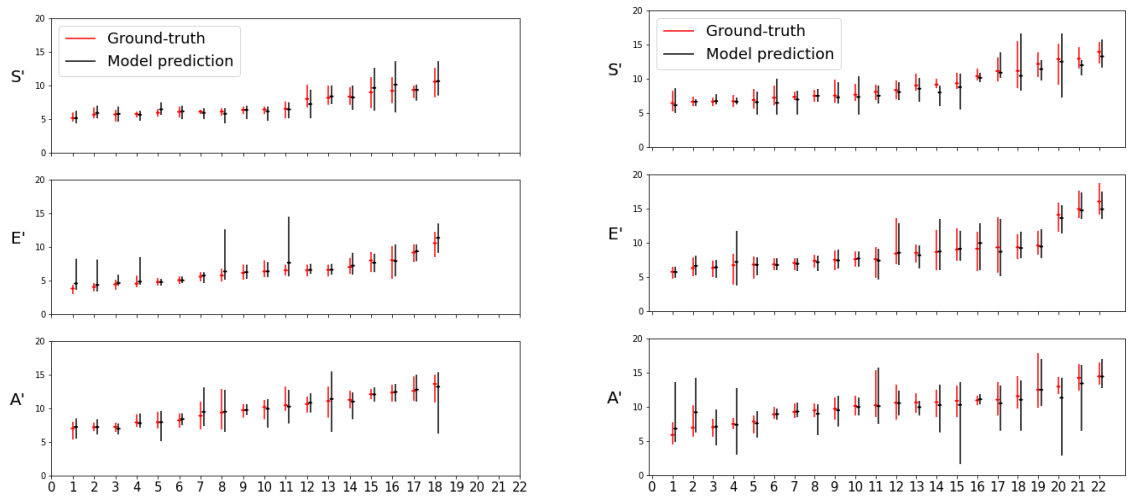

(a) Septal annulus (b) Lateral annulus

Figure 2: Average velocity estimates of expert consensus (ground-truth) vs. model.

Figure 2. shows mean septal S', E' and A' velocity estimates and standard deviations using the experts consensus (red) and the Model (black) for each patient. Circular markers

represent the mean and vertical bars represent the standard deviation. Patients have been placed in ascending order of the average velocity.
Table 1 details Bland–Altman bias and 95% limits of agreement when comparing expert annotations and Model predictions for peak tissue Doppler velocity measurements at the septal and lateral annulus.
We demonstrate the performance of the proposed Model is akin to human experts; detection error is within the range of calculated inter-observer variability, however processing time is greatly reduced. The dataset used in this study has been made public by the authors for the benefit of researchers and benchmarking of future studies (`https://intsav.github.io/tdi.html`).

Table 1: Bland–Altman bias and 95% limits of agreement comparing velocity measurements by Experts and Models

Model/Expert	Septal annulus			Lateral annulus		
	s'	e'	a'	s'	e'	a'
Human performance						
Exp 1,2 vs. Expert-3	0.13±0.59	-0.18±0.59	-0.06±0.84	0.33±0.91	0.15±0.92	0.11±0.84
Exp 1,3 vs. Expert-2	0.06±0.50	-0.22±0.60	0.29±0.70	0.33±0.87	0.12±0.80	0.17±0.75
Exp 2,3 vs. Expert-1	-0.19±0.63	-0.04±0.56	-0.24±0.69	-0.66±0.94	-0.27±0.77	-0.27±0.78
Expert consensus	-0.14±0.67	0.06±0.70	-0.08±0.90	-0.44±1.10	-0.19±0.97	-0.17±0.92
Machine performance						
Exp 1, 2 vs. Model-3	-0.01±0.82	-0.42±1.00	-0.11±0.85	0.59±0.93	0.08±1.32	0.38±1.87
Exp 1, 3 vs. Model-2	0.04±0.93	0.15±0.94	0.44±0.98	0.50±0.93	0.19±1.10	0.21±1.66
Exp 2, 3 vs. Model-1	-0.12±0.97	-0.17±0.94	-0.15±0.99	-0.11±1.02	-0.04±0.93	-0.04±1.35
Expert consensus vs. Model	-0.07±0.78	-0.22±0.92	-0.02±0.88	-0.38±0.81	-0.06±0.84	0.19±1.38

References

N. Dhutia, M. Zolgharni, M. Mielewczik, M. Negoita, S. Sacchi, K. Manoharan, D. Francis, and G. Cole. Open-source, vendor-independent, automated multi-beat tissue doppler echocardiography analysis. *International Journal of Cardiovascular Imaging*, 33(8):1135–1148, 2017.

J. Finegold, C. Manisty, F. Cecaro, N. Sutaria, J. Mayet, and D Francis. Choosing between velocity-time-integral ratio and peak velocity ratio for calculation of the dimensionless index (or aortic valve area) in serial follow-up of aortic stenosis. *International Journal of Cardiology*, 164(4):1524–1531, 2013.

S. Nagueh, C. Appleton, T. Gillebert, P. Marino, J. Oh, O. Smiseth, A. Waggoner, F. Flachskampf, P. Pellikka, and A.f Evangelisa. Recommendations for the evaluation of left ventricular diastolic function by echocardiography. *European Journal of Echocardiography*, 10(2):277–314, 2008.

M. Zolgharni, D. Francis, N. Dhutia, G. Cole, M. Bahmanyar, S. Jones, S. Sohaib, S. Tai, K. Willson, and J. Finegold. Automated aortic doppler flow tracing for reproducible research and clinical measurements. *IEEE Transactions on Medical Imaging*, 33(5):1071–1082, 2014.