High-resolution 3D Maps of Left Atrial Displacements using an Unsupervised Image Registration Neural Network

Author name(s) withheld EMAIL(S) WITHHELD
Address withheld

Editors: Under Review for MIDL 2023

Abstract

Functional analysis of the left atrium (LA) plays an increasingly important role in the prognosis and diagnosis of cardiovascular diseases. Echocardiography-based measurements of LA dimensions and strains are useful biomarkers, but they provide an incomplete picture of atrial deformations. High-resolution dynamic magnetic resonance images (Cine MRI) offer the opportunity to examine LA motion and deformation in 3D, at higher spatial resolution and with full LA coverage. However, there are no dedicated tools to automatically characterise LA motion in 3D. Thus, we propose a tool that automatically segments the LA and extracts the displacement fields across the cardiac cycle. The pipeline is able to accurately track the LA wall across the cardiac cycle with an average Hausdorff distance of 2.51 ± 1.3 mm and Dice score of 0.96 ± 0.02.

Keywords: Left Atrial, Image Registration Neural Network, Displacement Field Vector.

1. Introduction

The analysis of the anatomy and function of the left atrium (LA) is becoming more important for the prognosis and diagnosis of cardiac conditions such as atrial fibrillation (AF) or heart failure (HF) (Hoit, 2017; Peters et al., 2021). Structural characteristics of the LA are established atrial disease biomarkers (Varela et al., 2017) and analysis of LA deformations has been explored using speckle-tracking echocardiography (Smiseth et al., 2022). These biomarkers are typically obtained for a single LA view and spatial averages across LA wall regions. Spatiotemporal 3D maps of LA deformation are expected to provide more specific signatures of LA pathology, with greater diagnostic and prognostic value, as has been shown for the left ventricle (Duchateau et al., 2020). However, there are currently no publicly available MRI datasets or adequate image analysis tools to extract high-resolution displacement field vector (DFV) maps of the whole LA.

In this paper, we use a novel high-resolution Cine MRI protocol designed specifically for the LA. These Cine MRI offer information about the LA at higher spatial resolution than any existing databases. However, given that only a small amount of subjects have been imaged with this protocol, we utilize methods for limited number of training images.

Aim We propose the following pipeline to automatically obtain high-resolution 3D DFVs of the LA: 1) A few-shot segmentation network (LA-SNet) of the LA across the cardiac cycle to guide the registration; 2) Extraction of the LA segmentation contour and dilation; 3) An automatic subject-by-subject image registration of the LA contour image (LA-DNet).

© 2023 CC-BY 4.0, Anonymous.

2. Methods

2.1. Data

We use 3D LA Cine MRI bSSFP scans acquired using a novel acquisition protocol (Varela et al., 2020). In summary, they were acquired in a single breath-hold, resolution of $1.72 \times 1.72 \times 2.00\ mm^3$ and 20 phases across the cardiac cycle. Phase 0 corresponds to cardiac end diastole (smallest LA volume). As a proof of concept, we analyse images from six subjects: three healthy volunteers and three subjects with suspected cardiovascular disease.

2.2. Preprocessing

The images are cropped to a size of $96 \times 96 \times 36$ voxels, centered at the LA. Additionally, they are translated such that the LA centroid is stationary across the cardiac cycle and their intensity is min-max normalized. We manually segment the LA across the entire cardiac cycle to use as ground truth. From the segmentations, the contour is extracted and is dilated using a 2 voxels radius spherical structure, which is used to mask the images.

2.3. Model

Details of LA-SNet and LA-DNet are in Figure 1. For both models, we parameterise them empirically and use the Adam optimizer (Kingma and Ba, 2015) with default parameters. We set the learning rate to 0.001 with 0.8 decay rate and batch size to 1. The models are trained for 500 epochs on a subject by subject basis (separately for each subject). LA-DNet uses a bending energy regularizer (Rueckert et al., 1999) to improve the DFVs smoothness. The LA-SNet is trained on augmented cardiac phases 0, 8, and 15 (see Figure 1).

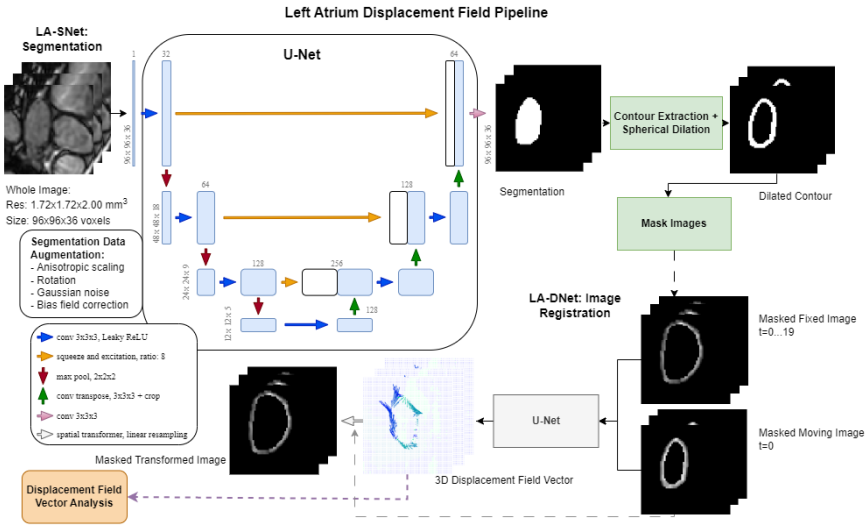

Figure 1: The proposed pipeline to extract high-resolution LA displacement field maps. The LA-SNet and LA-DNet share the same 3D convolutional U-Net architecture.

3. Results

LA-SNet can accurately segment the LA across the cardiac cycle, with an average Hausdorff distance (HD) of $3.03 \pm 1.12\ mm$ and Dice score (DS) of 0.95 ± 0.02. Similarly, LA-DNet is able to accurately track the LA wall across the cycle (see Figure 2). The LA segmentations

obtained when adding the estimated DVF to the LA segmentation in phase 0 compare extremely well with the GT segmentations: $HD = 2.51 \pm 1.3\ mm; DS = 0.96 \pm 0.02$. It outperformed previously used symmetric diffeomorphic image normalization from ANTs package (Avants et al., 2009) which obtained ($HD = 2.57 \pm 1.16\ mm; DS = 0.85 \pm 0.04$) to the same LA contour images and ($HD = 3.35 \pm 1.48\ mm; DS = 0.77 \pm 0.09$) when applied to the unsegmented LA images. Using LA-DNet directly on the unsegmented LA images as inputs also led to poor results ($HD = 3.35 \pm 1.05\ mm; DS = 0.78 \pm 0.07$). The LA-DNet estimated DFVs are spatially and temporally smoother and the Jacobian of the deformation gradient is consistent with the known volumetric changes of the LA, as can be seen in: https://tinyurl.com/2eju3r9f.

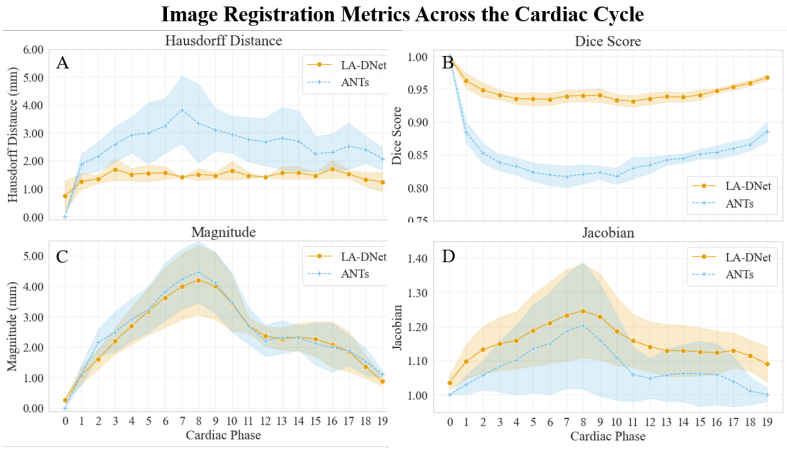

Figure 2: The image registration metrics plotted for LA-DNet and ANTs: A) Hausdorff distance (HD), B) Dice score (DS), C) magnitude of displacement field vectors (DFV), and D) Jacobian determinant of DFV. HD and DS are obtained by comparing manual LA segmentations across the cardiac cycle with segmentations transformed using the estimated DFV on phase 0.

4. Conclusions

The proposed pipeline is able to extract DFVs that accurately track the LA wall across the cardiac cycle. The estimated high-resolution 3D LA DFVs pave the way towards potentially detecting regional functional biomarkers for conditions such as AF or HF. They may also provide useful information for the identification of LA fibrosis (Sohns and Marrouche, 2020). The DVFs and their Jacobian of the proposed models have the expected properties, which is critical for such an analysis.

The LA registration across the cardiac cycle is more challenging than that of the LV. For the latter, several registration tools are available (Hernandez et al., 2021; De Vos et al., 2019), but performed poorly for the LA registration task. The usual assumption that the intensity of the different image components (e.g. the LV myocardium) is constant across the cardiac cycle, is not valid for the LA. This is because the LA myocardium is very thin (Varela et al., 2017), and thus barely identifiable in bSSFP images; and the LA blood pool voxels' intensity depends on blood velocity and is therefore very variable across the cardiac cycle. We successfully propose a different approach for automatically LA registration, using LA contours from automatic segmentations as inputs; and train it on a patient-by-patient basis to allow its deployment to small datasets of Cine MRI of the LA.

Acknowledgments

Acknowledgments withheld.

References

Brian B Avants, Nick Tustison, Gang Song, et al. Advanced normalization tools (ants). *Insight j*, 2(365):1–35, 2009.

Bob D De Vos, Floris F Berendsen, Max A Viergever, Hessam Sokooti, Marius Staring, and Ivana Išgum. A deep learning framework for unsupervised affine and deformable image registration. *Medical image analysis*, 52:128–143, 2019.

Nicolas Duchateau, Andrew P King, and Mathieu De Craene. Machine learning approaches for myocardial motion and deformation analysis. *Frontiers in cardiovascular medicine*, 6: 190, 2020.

Karen Andrea Lara Hernandez, Theresa Rienmüller, Daniela Baumgartner, and Christian Baumgartner. Deep learning in spatiotemporal cardiac imaging: A review of methodologies and clinical usability. *Computers in Biology and Medicine*, 130:104200, 2021.

Brian D Hoit. Evaluation of left atrial function: current status. *Structural Heart*, 1(3-4): 109–120, 2017.

Diederik P. Kingma and Jimmy Ba. Adam: A method for stochastic optimization. In Yoshua Bengio and Yann LeCun, editors, *3rd International Conference on Learning Representations, ICLR 2015, San Diego, CA, USA, May 7-9, 2015, Conference Track Proceedings*, 2015. URL http://arxiv.org/abs/1412.6980.

Dana C Peters, Jérôme Lamy, Albert J Sinusas, and Lauren A Baldassarre. Left atrial evaluation by cardiovascular magnetic resonance: sensitive and unique biomarkers. *European Heart Journal-Cardiovascular Imaging*, 23(1):14–30, 2021.

Daniel Rueckert, Luke I Sonoda, Carmel Hayes, Derek LG Hill, Martin O Leach, and David J Hawkes. Nonrigid registration using free-form deformations: application to breast mr images. *IEEE transactions on medical imaging*, 18(8):712–721, 1999.

Otto A Smiseth, Tomasz Baron, Paolo N Marino, Thomas H Marwick, and Frank A Flachskampf. Imaging of the left atrium: pathophysiology insights and clinical utility. *European Heart Journal-Cardiovascular Imaging*, 23(1):2–13, 2022.

Christian Sohns and Nassir F Marrouche. Atrial fibrillation and cardiac fibrosis. *European heart journal*, 41(10):1123–1131, 2020.

Marta Varela, Felipe Bisbal, Ernesto Zacur, Antonio Berruezo, Oleg V Aslanidi, Lluis Mont, and Pablo Lamata. Novel computational analysis of left atrial anatomy improves prediction of atrial fibrillation recurrence after ablation. *Frontiers in physiology*, 8:68, 2017.

Marta Varela, Sandro Queirós, Mustafa Anjari, Teresa Correia, Andrew P King, Anil A Bharath, and Jack Lee. Strain maps of the left atrium imaged with a novel high-resolution cine mri protocol. In *2020 42nd Annual International Conference of the IEEE Engineering in Medicine & Biology Society (EMBC)*, pages 1178–1181. IEEE, 2020.