Simultaneous Detection and Grading of Prostate Cancer in Multi-Parametric MRI

Coen de Vente[1,2] C.W.D.VENTE@STUDENT.TUE.NL
Pieter Vos[2] PIETER.VOS@PHILIPS.COM
Josien Pluim[1] J.PLUIM@TUE.NL
Mitko Veta[1] M.VETA@TUE.NL
[1] *Department of Biomedical Engineering, Eindhoven University of Technology, The Netherlands*
[2] *Philips Research, Eindhoven, The Netherlands*

1. Introduction

If there are indications that a patient has prostate cancer (PCa), a biopsy is ordered (Frankel et al., 2003). Gleason Grade Group (*GGG*), a predictor of pathological stage and oncological outcomes, (scale 1-5) is determined from the microscopic analysis of the biopsy samples (Epstein et al., 2016). With *GGG* 1 no treatment is usually needed and *GGG* 5 is the most severe type of PCa. Lesion grading from multi-parametric MRI (mpMRI) can decrease the number of biopsies. This is currently being done with the PIRADSv2 system. However, its inter-rater reliability remains moderate (Baldisserotto et al., 2016). The goal of the current study is to develop a more objective grading method from mpMRI.

In previous works, methods have been developed to detect PCa from mpMRI (Kohl et al., 2017; Liu et al., 2017; Tsehay et al., 2017). Other methods classify given lesions only as clinically significant or insignificant (Armato et al., 2018; Seah et al., 2017). Furthermore, techniques have been developed to grade suspicious regions indicated by radiologists (Armato et al., 2018; Yuan et al., 2018; Jensen et al., 2019). In this work, we propose an approach to perform both detection and grading. Furthermore, multiple methods to grade *GGG*s in mpMRI are evaluated, of which the best performing method, to best of our knowledge, has not previously been applied to *GGG* scoring.

2. Materials and methods

Dataset: We used the ProstateX-2 Challenge (PX-2) dataset for training, validation and testing. The challenge training set contains 99 patients and 112 lesions. The challenge test set contains 63 patients and 70 lesions. For every patient, mpMRI images were given. From the four types of scan data, we used T2-weighted (T2-w) and apparent diffusion coefficient (ADC). The challenge provided coordinates and *GGG*s of the training set lesions. Pathological analysis of MR targeted biopsy tissue provided the ground truth for the *GGG* scores. The aim of PX-2 was to assign a *GGG* to the lesions, given their coordinates. We manually delineated the lesions with in-house software that uses a semi-automated region growing technique.

© 2019 C. de Vente, P. Vos, J. Pluim & M. Veta.

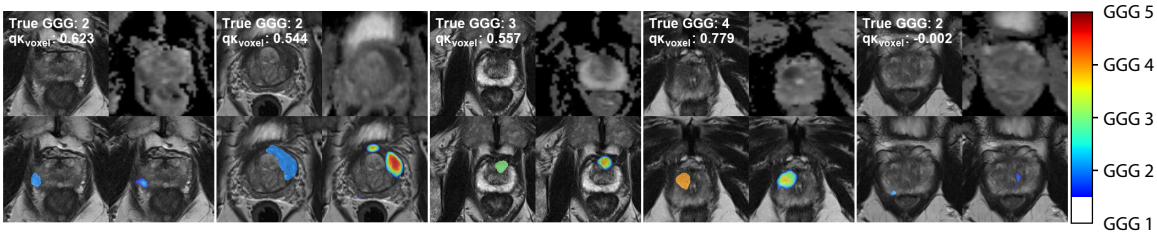

Figure 1: Qualitative results on the validation set using SLOR. Every image in the same 2×2 block represents the same middle slice of one lesion. The top right image is ADC, the other three are T2-w images. The bottom left overlay is the manual segmentation, and the bottom right overlay is the network prediction. Colormaps are transparent for *GGG* 1, as this is clinically equivalent to healthy tissue. $q\kappa_{voxel}$ is calculated on the displayed slice.

Pre-processing and CNN model: We cropped the images around the image center, such that the entire prostate and lesions were included in this region of interest (ROI). All ROIs were 90×90×80 mm^3 and resized to 192×192×32 voxels. 2D slices of the T2-w and ADC ROIs were the two input channels of the model. The T2-w images were normalized per individual image. As ADC images are quantitative, they were normalized over the entire dataset. We used the following data augmentation: elastic deformation, contrast changing, rotation, shearing, flipping along the vertical axis. We used a U-Net (Ronneberger et al., 2015) with batch normalization (Ioffe and Szegedy, 2015) after each convolutional layer.

Methods and experiments: Cross entropy loss and Adam were used in all experiments. We evaluated three different approaches for incorporating *GGG* scoring into the model. The last two models differ from the first one in that they take into account the ordinal nature of the problem. For example, if a lesion has *GGG* 4, the first method penalizes predictions of 1 and 3 equally, while the last two approaches penalize the former more than the latter. The size of each output channel in all three methods was the same as the same size of the input images. *Multiclass classification (MCC):* The network had five output channels, where each output channel corresponded to a *GGG*. *Multi-label ordinal regression (MLOR):* The network, as described by (Niu et al., 2016; Cheng et al., 2008), had 4 output channels, where the nth channel was 1 if the *GGG* is greater than n and 0 otherwise. *Soft-label ordinal regression (SLOR):* The target in this method was a single channel wherein each voxel had a scalar value in the range of 0 and 1. For every tumor T, the voxel within that tumor T had a value of $\frac{1}{4}(GGG_T - 1)$, where $GGG_T \in \{1, \ldots, 5\}$ is the *GGG* of tumor T. This method takes into account the ordinal nature of the problem, since the loss increases as the difference between a prediction and target value increases.

Evaluation: In this work, we developed a method that also detects the location of lesions, instead of simply grading, which is the aim of PX-2. The validation was done using 5-fold cross validation. To evaluate the model on the challenge test set, we also calculated lesion-wise *GGG* predictions for the coordinates given by the challenge. This was done by thresholding the prediction map ($GGG \geq 2$) and considering the connected components in a radius r of the requested coordinate. If no connected component was present in a radius r of the requested coordinate, a *GGG* of 1 was assigned to that lesion. Otherwise,

Table 1: Results of different approaches. Metrics are expressed as $\mu \pm \sigma$ of the different cross-validation folds. $q\kappa_{voxel}$ is the voxel-wise quadratic-weighted κ score. DSC is the Dice score after thresholding the prediction maps and target images with $GGG \geq 2$.

Method	$\boldsymbol{q\kappa_{voxel}}$	**DSC** ($\boldsymbol{GGG \geq 2}$)
MCC	0.225 ± 0.114	0.221 ± 0.104
MLOR	0.348 ± 0.050	0.303 ± 0.059
SLOR	**0.391 ± 0.062**	**0.321 ± 0.039**

$f_{prob \to GGG}(P_r)$ was used to predict the GGG, where P_r is the list of all the voxel values in the connected component within radius r of the requested coordinate and $f_{prob \to GGG}$ is a statistical measure. If the selection of the connected component was ambiguous, the largest connected component was chosen. We did a grid search by checking all permutations of $f_{prob \to GGG} \in \{90^{th}\ percentile, mean, max\}$ and $r \in \{0, 5, 10, 20, 30\}\ mm$. The input and predictions were not masked with a prostate segmentation.

3. Results

In Table 1, performance metrics of the different methods on the validation set are displayed. Fig. 1 shows randomly selected qualitative results of the SLOR approach. The grid search for $f_{prob \to GGG}$ and r showed the highest performance when using the 90th percentile for $f_{prob \to GGG}$ and choosing 5 mm for r. The lesion-wise quadratic-weighted κ ($q\kappa_{lesion}$) was 0.201 ± 0.257 ($\mu \pm \sigma$ of the 5-fold cross-validation iterations) using this method. On the PX-2 test set, which is not publicly available, SLOR had a performance of $q\kappa_{lesion} = 0.082 \pm 0.272$ ($\mu \pm \sigma$ calculated by the challenge organizers using bootstrapping with 1k iterations).

4. Discussion

We showed that the two ordinal regression approaches outperformed MCC. Furthermore, our proposed SLOR method was shown to perform better than MLOR, which is commonly used in literature for ordinal regression (Niu et al., 2016; Cheng et al., 2008). When converting the voxel-wise to lesion-wise predictions, $q\kappa_{lesion}$ drops. This could, for instance, be due to the method of this conversion, despite an extensive grid search. This could also be a result of small lesions being missed, which is not well reflected in the voxel-wise metric. The relatively low κ scores can be explained by the inherent ambiguity of this problem. Pathologists, even when grading from tissue biopsies, score an unweighted κ for inter- and intra-agreement of 0.54 and 0.66, respectively (Melia et al., 2006). Nevertheless, our grading method outperforms 30 out of 43 official submissions to PX-2, while solving a more difficult, but more clinically relevant, problem. A prostate segmentation was not masked with the input in our method, as that might exclude tumors that grow beyond the prostate border and essential information about the tumor aggressiveness might be missed. In future work we will explore the potential effect of including a prostate segmentation in other ways.

Acknowledgments

We thank the ProstateX-2 challenge organizers for providing the data used in this research, and for calculating the test results of our submission.

References

Samuel G Armato, Henkjan Huisman, Karen Drukker, Lubomir Hadjiiski, Justin S Kirby, Nicholas Petrick, George Redmond, Maryellen L Giger, Kenny Cha, Artem Mamonov, et al. PROSTATEx Challenges for computerized classification of prostate lesions from multiparametric magnetic resonance images. *Journal of Medical Imaging*, 5(4):044501, 2018.

Matteo Baldisserotto, Eurico J Dornelles Neto, Gustavo Carvalhal, Aloyso F de Toledo, Clovis M de Almeida, Carlos ED Cairoli, Daniel O de Silva, Eduardo Carvalhal, Ricardo P Paganin, Alexandre Agra, et al. Validation of PI-RADS v. 2 for prostate cancer diagnosis with MRI at 3T using an external phased-array coil. *Journal of Magnetic Resonance Imaging*, 44(5):1354–1359, 2016.

Jianlin Cheng, Zheng Wang, and Gianluca Pollastri. A neural network approach to ordinal regression. In *2008 IEEE International Joint Conference on Neural Networks (IEEE World Congress on Computational Intelligence)*, pages 1279–1284. IEEE, 2008.

Jonathan I Epstein, Michael J Zelefsky, Daniel D Sjoberg, Joel B Nelson, Lars Egevad, Cristina Magi-Galluzzi, Andrew J Vickers, Anil V Parwani, Victor E Reuter, Samson W Fine, et al. A contemporary prostate cancer grading system: a validated alternative to the gleason score. *European urology*, 69(3):428–435, 2016.

Stephen Frankel, George Davey Smith, Jenny Donovan, and David Neal. Screening for prostate cancer. *The Lancet*, 361(9363):1122–1128, 2003.

Sergey Ioffe and Christian Szegedy. Batch normalization: Accelerating deep network training by reducing internal covariate shift. *arXiv preprint arXiv:1502.03167*, 2015.

Carina Jensen, Jesper Carl, Lars Boesen, Niels Christian Langkilde, and Lasse Riis Østergaard. Assessment of prostate cancer prognostic Gleason grade group using zonal-specific features extracted from biparametric MRI using a KNN classifier. *Journal of applied clinical medical physics*, 2019.

Simon Kohl, David Bonekamp, Heinz-Peter Schlemmer, Kaneschka Yaqubi, Markus Hohenfellner, Boris Hadaschik, Jan-Philipp Radtke, and Klaus Maier-Hein. Adversarial Networks for Prostate Cancer Detection. *arXiv preprint arXiv:1711.10400*, 2017.

Saifeng Liu, Huaixiu Zheng, Yesu Feng, and Wei Li. Prostate cancer diagnosis using deep learning with 3D multiparametric MRI. In *Medical Imaging 2017: Computer-Aided Diagnosis*, volume 10134, page 1013428. International Society for Optics and Photonics, 2017.

J Melia, R Moseley, RY Ball, DFR Griffiths, K Grigor, P Harnden, M Jarmulowicz, LJ McWilliam, R Montironi, M Waller, et al. A UK-based investigation of inter-and intra-observer reproducibility of Gleason grading of prostatic biopsies. *Histopathology*, 48 (6):644–654, 2006.

Zhenxing Niu, Mo Zhou, Le Wang, Xinbo Gao, and Gang Hua. Ordinal regression with multiple output cnn for age estimation. In *Proceedings of the IEEE conference on computer vision and pattern recognition*, pages 4920–4928, 2016.

Olaf Ronneberger, Philipp Fischer, and Thomas Brox. U-net: Convolutional networks for biomedical image segmentation. In *International Conference on Medical image computing and computer-assisted intervention*, pages 234–241. Springer, 2015.

Jarrel CY Seah, Jennifer SN Tang, and Andy Kitchen. Detection of prostate cancer on multiparametric MRI. In *Medical Imaging 2017: Computer-Aided Diagnosis*, volume 10134, page 1013429. International Society for Optics and Photonics, 2017.

Yohannes K Tsehay, Nathan S Lay, Holger R Roth, Xiaosong Wang, Jin Tae Kwak, Baris I Turkbey, Peter A Pinto, Brad J Wood, and Ronald M Summers. Convolutional neural network based deep-learning architecture for prostate cancer detection on multiparametric magnetic resonance images. In *Medical Imaging 2017: Computer-Aided Diagnosis*, volume 10134, page 1013405. International Society for Optics and Photonics, 2017.

Yixuan Yuan, Wenjian Qin, Mark Buyyounouski, Bulat Ibragimov, Steve Hancock, Bin Han, and Lei Xing. Prostate Cancer Classification with Multi-parametric MRI Transfer Learning Model. *Medical physics*, 2018.