3D Body Composition Segmentation in Abdomen and Pelvis CT using Subdivided Labels and Random Patch

Author name(s) withheld EMAIL(S) WITHHELD
Address withheld

Editors: Under Review for MIDL 2023

Abstract

The distribution and volume of fat and muscle in APCT play an important role as a biomarker. In this study, APCT data from 200 individuals who underwent health screening was labeled into three classes of fat and four classes of muscle. Based on this labeling, 3D patch-wise segmentation was performed on the whole abdomen and pelvic scan images. The test results showed an overall class average of 0.89 DSC. This study conducted 3D whole-abdomen body composition segmentation using a total of eight segmented body composition labels including the background and verified its feasibility using random patches effective for the data and task.

Keywords: random patch, 3D, body composition, segmentation, APCT

1. Introduction

Body composition distribution is useful for the diagnosis and prognosis of the disease. Particularly, the analysis of the proportion and characteristics of fat and muscle in detail is important for the diagnosis of diabetes and sarcopenia. Since manually assessing the distribution of body composition requires a significant amount of labor, numerous deep learning methods have been developed for automated segmentation. Previous body tissue segmentation models used 2D images or small slab 3D volumes of abdominal-pelvic computer tomography (APCT) to reduce the computational load and labeling difficulty. (Weston et al., 2019; Koitka et al., 2021) In this study, we aimed to develop a 3D random patch-wise deep learning model for segmenting the entire 3D APCT into eight detailed types of fat and muscle tissues.

2. Materials and Methods

200 patients who visited the Gangnam Severance Hospital health promotion center between March 2021 and April 2021 and underwent APCT were selected. Segmentation classes were divided in detail into subcutaneous adipose tissue (SAT), visceral adipose tissue (VAT), external adipose tissue located outside the abdominal cavity (EAT), psoas muscles (PM), erector spinae muscles (ESM), multifidus muscles (MFM), remaining skeletal muscle classes except for the above muscle classes (SM), and background, which belongs to none of the aforementioned classes. 180 and 20 subjects were used for training and testing, respectively. Data pre-processing included resampling to isotropic resolution of 1.5mm, background cropping, normalization, and clamping between -300 and 500 in Hounsfield unit (HU).

V-Net (Milletari et al., 2016) was used for 3D segmentation of eight types of body tissues (including the background). At each epoch of training, the model received randomly

© 2023 CC-BY 4.0, Anonymous.

sampled 64x64x64 patches from 3D APCT images. This reduced the computational load and simplified the complexity of the whole abdominal pelvic image into patch units, allowing convolutional layers to easily learn the features of each patch. Primary training parameters were batch size = 16, Adam optimizer and Step scheduler with an initial learning rate of 0.01, step size of 20, and gamma of 0.1. Since the number of voxels substantially differs over the eight segmentation classes, we applied a hybrid loss that combines generalized dice (GD) loss and cross entropy (CE) loss to address class imbalance (Taghanaki et al., 2019). For inference, we input grid-sampled patches from the test data into the model and combined the outputs to create a single segmentation for the entire trunk image. Accuracy was evaluated based on the Dice Similarity Coefficient (DSC).

3. Experiments and Results

Table 1: Evaluation of Dice coefficient on the test set (P=patch size)

Class	**BG**	**SAT**	**SM**	**PM**	**VAT**	**EAT**	**ESM**	**MFM**	**Avg**
P=96_GD	0.883	0.744	0.656	0.887	0.770	0.702	0.853	0.876	0.796
P=64_GD	0.970	0.926	0.852	0.906	0.839	0.767	0.859	0.873	0.874
P=32_GD	0.973	0.930	0.824	0.695	0.767	0.666	0.714	0.502	0.759
P=64_GDCE	0.987	0.961	0.923	0.901	0.861	0.775	0.863	0.875	0.893

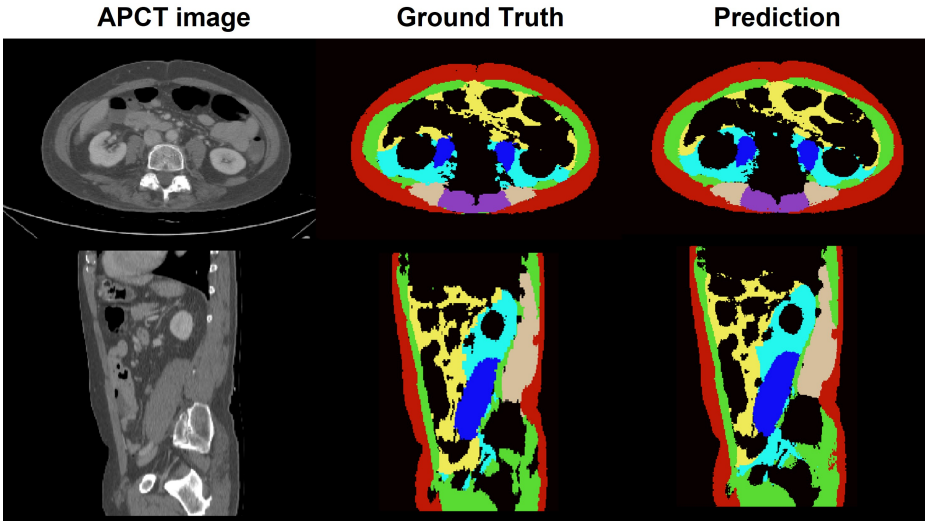

Figure 1: Axial and sagittal view images of the test subjects. SAT is indicated by red, VAT by yellow, EAT by light blue, SM by green, PM by blue, ESM by beige, and MFM by purple.

Table 1 summarizes the DSC values obtained from the test dataset. On average across all eight classes, the patch size of 64 achieved the best performance when only GD loss was used. The addition of CE loss improved the segmentation accuracy by penalizing false positives and negatives. Figure 2 shows a representative set of raw APCT images, ground truth segmentation images, and segmentation images predicted from the model for the axial and sagittal views. VAT-EAT and MFM-ESM classes appear to be challenging due to adjacent tissues with the same HU values. The prediction visualization results show that the model has smoothed out edges and discontinuities in the ground truth during the labeling process.

4. Conclusion

In summary, this study aimed to develop a deep learning approach for automated 3D whole abdomen body composition segmentation using a total of eight segmented body composition labels. The approach involved using random patch-wise data augmentation and a VNet model to improve generalization and accuracy. Results showed an overall class average of 0.89 DSC, demonstrating the feasibility of the approach.

Acknowledgments

Acknowledgments withheld.

References

Sven Koitka, Lennard Kroll, Eugen Malamutmann, Arzu Oezcelik, and Felix Nensa. Fully automated body composition analysis in routine ct imaging using 3d semantic segmentation convolutional neural networks. *European radiology*, 31:1795–1804, 2021.

Fausto Milletari, Nassir Navab, and Seyed-Ahmad Ahmadi. V-net: Fully convolutional neural networks for volumetric medical image segmentation. In *2016 fourth international conference on 3D vision (3DV)*, pages 565–571. Ieee, 2016.

Saeid Asgari Taghanaki, Yefeng Zheng, S Kevin Zhou, Bogdan Georgescu, Puneet Sharma, Daguang Xu, Dorin Comaniciu, and Ghassan Hamarneh. Combo loss: Handling input and output imbalance in multi-organ segmentation. *Computerized Medical Imaging and Graphics*, 75:24–33, 2019.

Alexander D Weston, Panagiotis Korfiatis, Timothy L Kline, Kenneth A Philbrick, Petro Kostandy, Tomas Sakinis, Motokazu Sugimoto, Naoki Takahashi, and Bradley J Erickson. Automated abdominal segmentation of ct scans for body composition analysis using deep learning. *Radiology*, 290(3):669–679, 2019.